



American College of  
Emergency Physicians®

ADVANCING EMERGENCY CARE 

# POLICY STATEMENT

Approved April 2023

## *Ultrasound Guidelines: Emergency, Point-of-care, and Clinical Ultrasound Guidelines in Medicine*

Revised April 2023,  
June 2016 with current  
title

Revised October 2008

Originally approved June  
2001 titled "Emergency  
Ultrasound Guidelines"

### Sections

1. Introduction
2. Scope of Practice
3. Training and Proficiency
4. Hospital Credentialing and Privileging
5. Specialty Certification
6. Quality and Ultrasound (US) Management
7. Value and Reimbursement
8. Clinical US Leadership in Healthcare Systems
9. Future Issues
10. Conclusion

### Tables

1. Emergency Medicine Ultrasound Definitions

### Figures

1. ACEP 2023 Emergency US Scope of Practice
2. Pathways for Clinical US Training, Credentialing, and Incorporation of New Applications
3. Clinical US Workflow

### Appendices

1. Evidence for Core Emergency US Applications
2. Evidence for Advanced Emergency US Applications
3. Emergency US Learning Objectives
4. Recommendations for EM Residency EUS Education Program
5. Recommendations for EUS Course
6. US in UME - Medical School Rotation and Curriculum

Copyright © 2023 American College of Emergency Physicians. All rights reserved.

## **Section 1 – Introduction**

Clinical ultrasound (CUS) has become an integral aspect of emergency care in the United States for over two decades. Since the last update of these guidelines in 2016, the role of US has expanded throughout clinical medicine. The wide breadth of recognized CUS applications offers both diagnostic and therapeutic benefits to patients around the world. Benefits of bedside imaging with ultrasound include its relatively low cost, lack of ionizing radiation, portability, and ease of use. Data have demonstrated that CUS can improve diagnostic accuracy in numerous common clinical presentations, including dyspnea,<sup>1</sup> abdominal pain,<sup>2</sup> and joint dislocations.<sup>3</sup> Ultrasound guidance has also been incorporated into bedside procedures, improving success and decreasing inadvertent complications.<sup>4-6</sup>

Emergency physicians have been leaders in innovation and education in the CUS space both nationally and internationally. This has led to increased integration and improved standardization at the undergraduate, postgraduate, and continuing medical education levels. Emergency medicine (EM) leaders have also leveraged their extensive knowledge and teaching to educate other specialties seeking to enhance their ultrasound training and expertise. Specifically, CUS curricula in undergraduate medical education is growing exponentially due to the leadership and advocacy of emergency physicians, integrating CUS into the education of the next generation of clinicians. In fact, CUS in EM residency training has been codified in the Model of the Clinical Practice of Emergency Medicine, a joint policy collaboration between seven organizations. Moreover, CUS fellowship has advanced with fellowships now eligible for accreditation by the Emergency Ultrasound Fellowship Accreditation Council (EUFAC) and fellowship graduates being recognized with certification as a focused practice designation by ABEM. Leaders in CUS have created the foundation of a subspecialty of ultrasonography that provides the expertise for establishing clinical practice, educating across the educational spectrum, and researching the wide range of applications. CUS leaders have also become instrumental in bringing health care systems into the future by championing and often running system-wide programs. As CUS continues to evolve and access to ultrasound machines becomes increasingly widespread, it is critical to understand the current field and provide national guidelines to inform education and practice. This guideline update is intended to provide a framework for new and established programs utilizing CUS.

## **Section 2 -- Scope of Practice**

CUS is the medical use of US technology for the bedside, clinical evaluation of acute or critical medical conditions.<sup>7</sup> It is utilized for diagnosis of any emergency condition such as the resuscitation of the critically ill patient, during guidance of procedures, and monitoring of certain pathologic states. CUS examinations are typically performed and interpreted by emergency physicians or those under the supervision of emergency physicians in the setting of the emergency department (ED) or a non-ED emergency setting hospital unit, out-of-hospital, battlefield, space, urgent care, clinic, or remote or other settings). It may be performed as a single examination, repeated serially due to clinical need or patient deterioration, or used for monitoring of physiologic or pathologic changes.

In this document, CUS refers to US performed by emergency physicians or clinicians in the emergency setting, while point-of-care ultrasound (POCUS) refers to a multidisciplinary field of US use by clinicians at the point-of-care.<sup>8</sup> Table 1 summarizes relevant US definitions in CUS.

Other medical specialties may wish to use this document if they perform CUS in the manner described above. However, guidelines which apply to US examinations or procedures performed by consultants, especially consultative imaging in US laboratories or departments, or in alternative settings may not be applicable to emergency physicians.

Emergency US (EUS) is an emergency medicine procedure, and should not be considered in conflict with exclusive “imaging” contracts that may be in place with consultative US practices. In addition, emergency US should be reimbursed as a separate billable procedure.<sup>9</sup> (See Section 7- Value and Reimbursement)

CUS is a separate entity distinct from the physical examination that adds anatomic, functional, and physiologic information to the care of the acutely-ill patient.<sup>10</sup> It provides clinically significant data not obtainable by inspection, palpation, auscultation, or other components of the physical examination.<sup>11</sup> US used in this clinical context is also not equivalent to use in the training of medical students and other clinicians in training looking to improve their understanding of anatomic and physiologic relationships of organ systems.

CUS can be classified into the following functional clinical categories:

1. *Resuscitative*: US use as directly related to an acute resuscitation
2. *Diagnostic*: US utilized in an emergent diagnostic imaging capacity
3. *Symptom or sign-based*: US used in a clinical pathway based upon the patient’s symptom or sign (eg, shortness of breath)
4. *Procedure guidance*: US used as an aid to guide a procedure
5. *Therapeutic and Monitoring*: US use in therapeutics or in physiological monitoring

Within these broad functional categories of use, 15 core emergency US applications have been identified as Aorta, Bowel, Cardiac/Hemodynamic assessment, Deep Vein Thrombosis (DVT), Hepatobiliary, Musculoskeletal (MSK), Ocular, Pregnancy, Procedural Guidance, Skin and Soft-tissue, Testicular, Thoracic/Airway, Trauma, Ultrasound-Guided Nerve Blocks, and Urinary Tract. Evidence for these core applications may be found in Appendix 1. The criteria for a core application are widespread use, significant evidence base, uniqueness in diagnosis or decision-making, importance in primary emergency diagnosis and patient care, or technological advance.

Alternatively, symptom and sign based US pathways, such as Shock or Dyspnea, may be considered an integrated application based on the skills required in the pathway. In such pathways, applications may be mixed and utilized in a format and order that maximizes medical decision-making, outcomes, efficiency and patient safety tailored to the setting, resources, and patient characteristics. See Figure 1.

Emergency physicians should have basic education in US physics, knobology, instrumentation procedural guidance, and Focused Assessment with Sonography in Trauma (FAST) as part of EM practice. It is not mandatory that every clinician performing emergency US examinations utilize or be expert in each core application, but it is understood that each core application is incorporated into common emergency US practice nationwide. The descriptions of these examinations may be found in the ACEP policy, Emergency Ultrasound Imaging Criteria Compendium.<sup>12</sup> Many other US applications or advanced uses of these applications may be used by emergency physicians. Their non-inclusion as a core application does not diminish their importance in practice nor imply that emergency physicians are unable to use them in patient care.

Each EUS application represents a clinical bedside skill that can be of great advantage in a variety of emergency patient care settings. In classifying an emergency US, a single application may appear in more than one category and clinical setting. For example, a focused cardiac US may be utilized to identify a pericardial effusion in the diagnosis of an enlarged heart on chest x-ray. The focused cardiac US may be utilized in a cardiac resuscitation setting to differentiate true pulseless electrical activity from profound hypovolemia. The focused cardiac US can be used to monitor the heart during resuscitation in response to fluids or medications. If the patient is in cardiac tamponade, the cardiac US can also be used to guide a pericardiocentesis. In addition, the same focused cardiac study can be combined with one or more additional

emergency US types, such as the focused abdominal, the focused aortic or the focused chest/thoracic US, into a clinical algorithm for an undifferentiated hypotensive patient. See Figure 1.

Ultrasound guidance provides added safety to a wide variety of procedures ranging from vascular access (eg, central venous access) to drainage procedures (eg, thoracentesis pericardiocentesis, paracentesis, arthrocentesis) to localization procedures like US guided nerve blocks. These procedures may provide additional benefits by increasing patient safety and helping alleviate acute pain.

Other US applications are performed by emergency physicians, and may be integrated depending on the setting, training, and needs of that particular ED or EM group.

### Other Settings or Populations

**Pediatrics.** CUS is a particularly advantageous diagnostic tool in the management of pediatric patients, in whom radiation exposure is a significant concern. CUS applications such as musculoskeletal evaluation for certain fractures (rib, forearm, skull), and lung for pneumonia may be more advantageous in children than in adults due to smaller patient size and density.<sup>13</sup> US can be associated with increased procedural success and patient safety, and decreased length of stay.<sup>14,15</sup> While most US modalities in the pediatric arena are the same as in adult patients (the EFAST exam for trauma, procedural guidance), other modalities are unique to the pediatric population such as in suspected pyloric stenosis and intussusception, or in the child with hip pain or a limp).<sup>16-18</sup> Mostly recently, EUS has been formally incorporated into Pediatric EM fellowship training.<sup>19,20</sup>

**Critical Care.** CUS core applications are being integrated into cardiopulmonary resuscitations and non-invasive hemodynamic monitoring into critical care scenarios.<sup>21,22</sup> Dual-trained physicians in emergency medicine and critical care are leading the application, education, and research of US for critically ill patients, and have significant leadership in advancing US concepts in multidisciplinary critical care practice. Advanced cardiopulmonary US application are being integrated into critical care practice.

**Prehospital.** There is increasing evidence that CUS has an increasing role in out-of-hospital emergency care.<sup>23,24</sup> Challenges to the widespread implementation of out-of-hospital US include significant training and equipment requirements, and the need for oversight and quality assurance. Studies focusing on patient outcomes need to be conducted to further define the role of out-of-hospital CUS and to identify settings where the benefit to the patient justifies the investment of resources necessary to implement such a program.<sup>25</sup>

**International arena including field, remote, rural, global public health and disaster situations.** US has become the primary initial imaging modality in disaster care.<sup>26-30</sup> US can direct and optimize patient care in natural disasters such as tsunamis, hurricane, famine or man-made disasters such as battlefield or refugee camps. US allows for imaging in remote locations such as rural areas, developing countries, or small villages which often do not have other imaging options (eg, x-ray, CT, MRI), unreliable electrical supplies, and less experienced clinicians. US in outer space is often the only imaging modality for space exploration and missions.<sup>31,32</sup> Ultrasound has also been used in remote settings such as international exploration, mountain base camps, and cruise ships.<sup>23</sup> The increasing portability of US machines and development of handheld devices with improving image resolution has expanded the use of emergent imaging in such settings.

**Military and Tactical.** The military has embraced the utilization of US technology in austere battlefield environments.<sup>33,34</sup> It is now routine for combat support hospitals as well as forward surgical teams to deploy with next generation portable ultrasonography equipment. Clinical ultrasonography is often used to inform decisions on mobilization of casualties to higher echelons of care and justify use of limited resources. Within the last decade, emergency physicians at academic military medical centers have expanded ultrasonography training to clinical personnel who practice in close proximity to the point of injury, such as combat medics,

special operations forces, physician assistants, and nurse practitioners.<sup>35</sup> The overarching goal of these training programs is to create a generation of competent clinical sonologists capable of practicing “good medicine in bad places.” The military is pursuing telemedicine-enabled US applications, automated US interpretation capabilities, and extension of clinical ultrasonography in additional areas of operation, such as critical care air evacuation platforms.<sup>36</sup>

### **Section 3 – Training and Proficiency**

Training in CUS often begins today in undergraduate medical education (UME) where students first learn and practice the basics of sonography as part of their anatomy, pathophysiology, and physical exam coursework.<sup>37</sup> During Graduate Medical Education (GME), clinicians increasingly learn to utilize CUS applications specific to their specialty and practice environment.<sup>38-40</sup> Finally, clinicians continue to learn evolving applications and new technologies through decades of practice.<sup>41</sup>

### **Competency and Curriculum Recommendations**

Competency in CUS requires the progressive development and application of increasingly sophisticated knowledge and psychomotor skills.<sup>42,43</sup> First, the clinician needs to recognize the indications and contraindications. Next, the clinician must be able to acquire adequate images. This begins with an understanding of basic US physics, translated into the skills needed to operate the US system correctly (knobology), while performing CUS application protocols on patients presenting with different conditions and body habitus. Simultaneous with image acquisition, the clinician needs to interpret the imaging by distinguishing normal anatomy, common variants, as well as a range of pathology from obvious to subtle. Finally, the clinician must be able to integrate EUS exam findings into their medical decision-making. Ultimately, this integration includes detailed knowledge of each particular exam’s accuracy, as well as proper documentation for the medical record, credentialing, quality assurance, and reimbursement.

Given the continual advances in CUS, designing and implementing a comprehensive yet efficient curriculum for diverse learners requires considerable faculty expertise, dedicated non-clinical time, and ongoing department support. These updated guidelines continue to provide the learning objectives (See Appendix 2), educational methods, and assessment measures for a EUS residency or practice-based curriculum.

### **Evolving Educational Methods**

Accelerated by necessity during the COVID-19 pandemic, innovative educational methods increasingly supplement more traditional education methods in EUS training.<sup>44</sup> Free open-access medical (FOAM) education, including carefully curated narrated lectures, podcasts and blogs, help educators create an engaging flipped clinical classroom.<sup>45-48</sup> For the trainee, asynchronous learning provides the opportunity to review required knowledge on-demand and at their own pace. For teachers, less time may be spent providing recurring didactics and more time dedicated to higher-level tasks such as teaching psychomotor skills and integration of exam findings into patient and ED management.

Similar to knowledge learning, there are new educational methods to teach the required psychomotor skills of EUS. The primary educational method continues to be small group hands-on training in the ED with CUS faculty, followed by supervised examination performance during clinical work, with timely quality assurance review and feedback. Simulation continues to play an important role as both an educational method and assessment measure.<sup>43,44,49,50</sup> Investigators have demonstrated that simulation results in equivalent image acquisition, interpretation, and operator confidence in comparison to traditional hands-on training. Simulation provides the opportunity for deliberate practice of a new skill in a safe environment prior to actual clinical performance. The use of simulation for deliberate practice improves the success rate of invasive procedures

and reduces patient complications. Additionally, simulation has the potential to expose trainees to a wider spectrum of pathology and common variants than typically encountered during a POCUS rotation. Blended learning created by the flipped classroom, live instructor training, and simulation provide the opportunity for self-directed learning, deliberate practice and mastery learning.<sup>51-53</sup> Furthermore, gamification provides the opportunity to actively engage learners while assessing and ultimately teaching clinical ultrasound knowledge and skills.<sup>54,55</sup>

### Documenting Experience and Demonstrating Proficiency

Traditional set number benchmarks for procedural training in medical education have historically provided a convenient method for documenting the performance of a reasonable number of exams needed for a trainee to develop competency.<sup>43</sup> However, learning curves vary by trainee and application. Individuals learn the required knowledge and psychomotor skills at their own unique pace. Supervision, opportunities to practice different applications, and encounter pathology also likewise differ across departments.

Therefore, additional assessment measures need to be utilized in addition to set number benchmarks.<sup>43,56</sup> Recommended methods include the following: real-time supervision during clinical EUS, weekly quality assurance (QA) image review sessions, ongoing individual QA image review exam feedback, standardized knowledge assessments, small group Observed Structured Clinical Examinations (OSCEs), one-on-one standardized direct observation tools (SDOTs), and simulation assessments.<sup>57</sup> Ideally these assessment measures are completed both at the beginning and the end of a training period. Initial assessment measures identify each trainee's unique needs, providing the opportunity to modify a local curriculum as needed to create more individualized learning plans. Final assessment measures demonstrate current trainee competency and future learning needs, identify opportunities for curriculum improvement, and ideally are supported by patient outcomes.<sup>56</sup>

***Trainees should complete a benchmark of 25-50 quality-reviewed exams in a particular application.*** Any individual clinician's learning curve may plateau below or above a set number benchmark for competency. With continued deliberate practice, proficiency will continue to slowly improve along the asymptotic line of expertise throughout a clinician's career.<sup>58</sup> Previously learned knowledge and psychomotor skills will often facilitate the learning and performance of new applications. For example, experience with FAST provides a springboard application to learning the genitourinary, transabdominal pelvic, and resuscitative clinical ultrasound applications.

***Overall EUS trainees should complete a minimum benchmark of 150-300 total clinical US exams depending on the number of applications being utilized.*** For example, an academic department regularly performing greater than six applications may require residents to complete more than 150 exams, while a community ED with practicing physicians just beginning to incorporate EUS with FAST and vascular access may initially require less.

If alternative techniques are being used for an application, for example an endocavitary probe in early pregnancy evaluation, the minimum for that application should include substantial experience in that alternative technique. Trainees should complete a minimum of 10-15 examinations in the alternative technique during the completion of the 25-50 exams, since learning to properly interpret the anatomy and pathology occurs with each technique taught in a particular application.

Procedural US applications require fewer exams given prior knowledge, psychomotor skills, and clinical experience with the traditional landmark-based techniques. Trainees should complete five quality reviewed US-guided procedure exams or a learning module on an US-guided procedure task trainer.

Training exams need to include clinical and simulated patients with different conditions and body types. Exams may be completed in different settings including clinical and educational patients in the ED, live models at EUS courses, utilizing US simulators, and in other clinical environments. In-person supervision is optimal during introductory education but is not required for residency or credentialing examinations after initial didactic and supervised skills training. Evolving technologies now create the opportunity for remote supervision and feedback even in resource-limited settings.<sup>59-61</sup> Abnormal or otherwise positive scans need to be included during the completion of training exams used to meet credentialing requirements. When pathology is not encountered during patient care, common variants and pathologic findings need to be reviewed during QA or other educational sessions.

During benchmark completion (credentialing phase), all EUS exams should be quality reviewed for technique and accuracy by EUS faculty. Alternatively, an EUS training portfolio of exam images and results may be compared to other diagnostic studies and clinical outcomes in departments where EUS faculty are not yet available. After initial training, continued quality assurance of EUS exams is recommended for a proportion (5-10%) of ongoing exams to document continued competency. Secure online systems facilitate image review and QA feedback, while also improving workflow, utilization, documentation, and reimbursement.<sup>62</sup>

### **Training Pathways**

There are two recommended pathways for clinicians to become proficient in EUS. See Figure 2. The majority of emergency physicians today receive EUS training as part of an ACGME-approved EM residency. A second practice-based pathway is provided for practicing EM physicians and other clinicians who did not receive training during residency.

These updated EUS guidelines continue to provide the learning objectives, educational methods and assessment measures for either pathway. Learning objectives for each application are described in Appendix 3.

### ***Residency Based Pathway***

EUS has been considered a fundamental component of emergency medicine training for over two decades.<sup>63,64</sup> The ACGME mandates procedural competency in EUS for all EM residents as it is a “skill integral to the practice of Emergency Medicine.” Although the ACGME EM Milestones 2.0 project now includes ultrasound within Patient Care Milestone eight, ABEM is currently working with emergency POCUS leaders to better delineate diagnostic and procedural ultrasound within the Emergency Medicine Model of Clinical Practice.<sup>65</sup> Appendix 4 provides recommendations for EM residency EUS education.

Upon completion of residency training, emergency medicine residents should be provided with a standardized EM Resident EUS credentialing letter. For the EUS faculty or ED Director at the graduate’s new institution, this letter provides a detailed description of the EUS training curriculum completed, including the number of quality reviewed training exams completed by application and overall, and performance on SDOTs and simulation assessments. Example letters and other EUS program and education resources can be found at <https://www.acep.org/emultrasound/resources/running-a-program/>.

### ***Practice-Based Pathway***

For practicing EM attendings who completed residency without specific EUS training, a comprehensive longitudinal curriculum, multi-day course, series of short courses, or preceptorship is recommended.<sup>66</sup> Shorter courses covering single or a combination of applications may provide initial or supplementary training.<sup>67</sup> As part of pre-course preparation, EUS faculty must consider the unique learning needs of the participating

trainees. The course curriculum should include trainee-appropriate learning objectives, educational methods and assessment measures as outlined by these guidelines. If not completed previously, then introductory training on US physics and knobology is required prior to training in individual applications. Pre-course and post-course online learning may be utilized to reduce the course time spent on traditional didactics and facilitate later review. Small group hands-on instruction with EUS faculty on models, simulators, and task trainers provides experience in image acquisition, interpretation, and integration of EUS exam findings into patient care. See Appendix 5.

Preceptorships typically lasting 1-2 weeks at an institution with an active EUS education program have also been utilized successfully to train practicing physicians. Each preceptorship needs to begin with a discussion of the trainees' unique educational needs, hospital credentialing goals as well as financial support for faculty teaching time. Then the practicing physician participates in an appropriately tailored curriculum typically in parallel with ongoing student, resident, fellow and other educational programming.

Similar to an EM Resident EUS credentialing letter, course and preceptorship certificates should include a description of the specific topics and applications reviewed, total number of training exams completed with expert supervision, performance on other course assessment measures such as SDOTs or simulation cases, as well as the number of CME hours earned. These certificates are then given to local EUS faculty or ED directors to document training.

### **Physician Assistants, Nurse Practitioners, Nurses, Paramedics, and other EM clinicians**

In many practice environments, EUS faculty often provide POCUS training and ongoing support to other clinicians including Physician Assistants, Nurse Practitioners, Nurses, Paramedics, Military Medics and Disaster Response Team members. Supervision should align with that defined by the ACEP policy statement, Guidelines Regarding the Role of Physician Assistants and Nurse Practitioners in the Emergency Department.<sup>68</sup> The recommendations in these ACEP guidelines should be utilized by EUS faculty when providing such training programs. Pre-course preparation needs to include discussions with staff leadership to define role-specific learning needs and applications to be utilized. Introductory US physics, knobology, and relevant anatomy and pathophysiology are required prior to training in targeted applications.

### **Ongoing Education**

As with all aspects of EM, ongoing education is required regardless of training pathway. The amount of education needed depends on the number of applications being performed, frequency of utilization, the local practice of the individual clinician, and developments within EUS and EM. Individual EUS credentialed physicians should continue their education with a focus on EUS learning as a recurring component of educational activities. Educational sessions that integrate EUS into daily practice are encouraged and do not have to be didactic in nature, but instead may be hands-on or online. Recommended EUS educational activities include EUS conference attendance, online educational activities, preceptorships, teaching, research, hands-on training, program administration, quality assurance, image review, written examinations, textbook and journal readings, as well as morbidity and mortality conferences inclusive of EUS cases. EUS quality improvement is an example of an activity that may be used for the completion of the required ABEM Improvement in Medical Practice Activity.

### **Fellowship Training**

***Fellowships provide the advanced training needed to create future leaders in evolving areas of medicine such as EUS. This advanced training produces experts in EUS and is not required for the routine utilization of EUS.***



An Advanced Emergency Medicine Ultrasonography (AEMUS) fellowship provides a unique, focused, and mentored opportunity to develop and apply a deeper comprehension of advanced principles, techniques, applications, and interpretative findings. Knowledge and skills are continually reinforced as the fellow learns to effectively educate new trainees in EUS, as well as clinicians in other specialties and practice environments. A methodical review of landmark and current literature, as well as participation in ongoing research, creates the ability to critically appraise and ultimately generate the evidence needed for continued improvements in patient care through CUS. Furthermore, a fellowship provides practical experience in EUS program management including quality assurance review, medical-legal documentation, image archiving, reimbursement, equipment maintenance, and other administrative duties of an EUS program director or System-Wide CUS Director.<sup>69</sup>

Recommendations for fellowship content, site qualifications, criteria for fellowship directors, and minimum graduation criteria for fellows have been published by national EUS leaders and within the ACEP Emergency Ultrasound Fellowship Guidelines. Each fellowship program's structure and curriculum will vary slightly based on local institution and department resources. ABEM has helped to standardize AEMUS fellowships through a fellowship program accreditation process involving EUFAC (Emergency Ultrasound Fellowship Accreditation Council).<sup>70</sup> ACEP participates in this as a nominating organization to EUFAC. At all fellowship programs, mentorship and networking are fundamental to a fellow's and program's ultimate success. Both require significant EUS faculty time for regular individual instruction as well as participation in the clinical US community locally and nationally. Accredited fellowships are required to supply sufficient US faculty support to maintain the training environment. Hence, institution and department leadership support is essential to ensuring an appropriate number of EUS faculty, each provided with adequate non-clinical time.

For the department, a fellowship speeds the development of an EUS program. Fellowships improve EM resident training resulting in increased performance of EUS examinations. Furthermore, a fellowship training program may have a significant positive impact on overall EUS utilization, timely QA review, faculty credentialing, billing revenue, and compliance with documentation. For an institution, an EUS fellowship provides a valuable resource for other specialties just beginning POCUS programs. Collaborating with EUS faculty and fellows, clinicians from other departments are often able to more rapidly educate staff and create effective POCUS programs.

Advanced Emergency Medicine Ultrasonography was approved as a Focused Practice Designation (FPD) by the American Board of Medical Specialties in 2017. To be eligible for FPD certification in Advanced Emergency Medicine Ultrasonography, EUS fellows must be board certified by ABEM in EM and complete a EUS Fellowship that has been accredited by the new Emergency Ultrasound Fellowship Accreditation Council. After graduating, qualified fellows are then eligible to take the Advanced Emergency Medicine Ultrasonography Fellowship Examination now offered by ABEM to earn their FPD certification.<sup>71,72</sup>

## **US in Undergraduate Medical Education**

EM faculty often lead efforts to improve Undergraduate Medical Education (UME) through the early integration of US. During the preclinical years, US has been demonstrated to be an effective educational method to reinforce student understanding of anatomy, physical examination skills, pathology and bedside diagnostic skills. During the clinical years, these students are able to utilize POCUS for clinical diagnosis on specific rotations. US exposure in UME can provide a solid foundation for the integration of POCUS into their clinical practice during Graduate Medical Education (GME).

### ***Integrating US into UME***

Integration of US into pre-clinical UME often begins with medical student and faculty interest.<sup>73</sup> By working

closely with a medical school's curriculum committee, US may then be incorporated as an engaging hands-on educational method to enhance learning within existing preclinical courses. Widespread POCUS utilization by different specialties within a medical school's teaching hospitals often helps to provide the needed faculty time and expertise, teaching space, and US equipment. Ongoing annual education then requires local departmental and medical school leadership support, as well as continued organized collaboration between faculty from participating specialties.

Innovative educational methods again provide the opportunity for clinical US faculty to focus on small group hands-on instruction as described in the innovative education section. Many academic departments that currently offer clinical rotations within EM already include an introduction to EUS as a workshop or a set number of EUS shifts. Dedicated EUS elective rotations provide an additional opportunity for medical students interested in EM and other specialties utilizing POCUS to participate in an EUS rotation adapted to their level of training and unique career interests. See Appendix 6 for recommendations for POCUS medical school rotations.

### ***US in UME continuing into POCUS in GME***

UME US experience should prepare new physicians to more rapidly utilize POCUS to improve patient care during graduate medical education (GME) training. Medical students therefore should graduate with a basic understanding of US physics, machine operation, and common exam protocols such as US guided vascular access. Medical students matriculating from a school with a detailed integrated US curriculum across the pre and clinical years, as well as those completing an elective POCUS rotation, should be provided with a supporting letter describing didactics, hands-on training, and total examinations. Although all trainees need to complete the EUS residency requirements, trainees with basic proficiency in US from UME training may progress more rapidly and ultimately achieve higher levels of EUS expertise during GME. Additionally, these residents may provide considerable EUS program support as peer-to-peer instructors, residency college leaders, investigators and potentially future fellows.

### **Section 4 – Hospital Credentialing and Privileging**

Implementing a transparent, high-quality, verifiable and efficient credentialing system is an integral component of an EUS program. The medical staff at a hospital are governed by bylaws. Included within these bylaws are credentialing and re-credentialing requirements and responsibilities, including the delineation of privileges of clinicians. A high quality and verifiable credentialing process is a duty owed by a hospital to its patients. The hospital can be deemed negligent in the event of a bad patient outcome if the credentialing process is found to be deficient.

An EUS director, along with the department leadership, should develop policies and guidelines pertaining to EUS. The department should follow the specialty-specific guidelines set forth within this document for their credentialing and privileging process. Pertaining to clinician performed US, the American Medical Association (AMA) House of Delegates in 1999 passed a resolution (AMA Res. 802, I-99) recommending hospitals' credentialing committees follow specialty-specific guidelines for hospital credentialing decisions related to US use by clinicians.<sup>74</sup> This resolution became AMA policy, Privileging for Ultrasound Imaging,<sup>74</sup> and affirms that US imaging is within the scope of practice of appropriately trained physician specialists and provides clear support for hospital credentialing committees to grant EUS privileging based on the specialty-specific guidelines contained within this document without the need to seek approval from other departments. Furthermore, HR 802 states that opposition that is clearly based on financial motivation meets criteria to file an ethical complaint to the AMA.

The provision of clinical privileges in EM is governed by the rules and regulations of the department and institution for which privileges are sought. The EM Chairperson or Medical Director or his/her designee (eg, EUS director) is responsible for the assessment of CUS privileges of emergency physicians. When a physician applies for appointment or reappointment to the medical staff and for clinical privileges, including renewal, addition, or rescission of privileges, the reappraisal process must include assessment of current competence. The EM leadership will, with the input of department members, determine how each emergency physician will maintain competence and skills and the mechanism by which each physician is monitored.

EM departments should list EUS within their core EM privileges as a single separate privilege for “Emergency US” or US applications can be bundled into an “US core” and added directly to the core privileges. EM should take responsibility to designate which core applications it will use, and then track its emergency physicians in each of those core applications. To help integrate physicians of different levels of sonographic competency (graduating residents, practicing physicians, fellows and others), it is recommended that the department create a credentialing system that gathers data on individual physicians, which is then communicated in an organized fashion at predetermined thresholds with the institution-wide credentialing committee. This system focuses supervision and approval at the department level where education, training, and practice performance is centered prior to institutional final review. As new core applications are adopted, they should be granted by an internal credentialing system within the department of emergency medicine.

Eligible clinicians to be considered for privileging in EUS include emergency physicians, physician assistants, nurse practitioners, or other healthcare workers who complete the necessary training as specified in this document via residency training or practice-based training (see Section 3 – Training and Proficiency). After completing either pathway, these skills should be considered a core privilege with no requirement except consistent utilization and ongoing education. At institutions that have not made EUS a core privilege, submission of 5-10% of the initial requirement for any EUS application is sufficient to demonstrate continued proficiency.

Sonographer certification or EUS certification by external entities is not an expected, obligatory or an encouraged requirement for EUS credentialing.<sup>75</sup> Those physicians who specialize in AEMUS will have acquired a greater breadth and depth of knowledge in advanced techniques, research, and quality improvement skills. The FPD recognizes expertise held by emergency physicians with sophisticated, comprehensive knowledge of advanced emergency ultrasonography and is available only to ABEM-certified physicians.

Regarding re-credentialing or credentialing at a new health institution or system, ACEP recommends that once initial training in residency or by practice pathway is completed, credentialing committees recognize that training as a core privilege, and ask for proof of recent updates or at most a short period of supervision prior to granting full privileges.

In addition to meeting the requirements for ongoing clinical practice set forth in this document, physicians should also be assessed for competence through the CQI program at their institution. (See Section 6-Quality and US Management) The Joint Commission (TJC) in 2008 implemented a new standard mandating detailed evaluation of practitioners’ professional performance as part of the process of granting and maintaining practice privileges within a healthcare organization.<sup>76</sup> This standard includes processes including the Ongoing Professional Practice Evaluation (OPPE) and the Focused Professional Practice Evaluation (FPPE). Specific to FPPE and US credentialing, for infrequently performed US examinations, FPPE monitoring can be performed on a predetermined number of examinations (ie, review of the diagnoses made on the first 10 or 20 of a particular US examination). The FPPE process should: 1. Be clearly defined and documented with specific criteria and a monitoring plan; 2. Be of fixed duration; and 3. Have predetermined measures or

conditions for acceptable performance. OPPE can incorporate EUS quality improvement processes. US directors should follow these guidelines when setting up their credentialing and privileging processes.

### **Section 5 – Specialty Certification**

ABEM instituted specialty certification using a focused practice designation (FPD) pathway in 2021. ABMS created the FPD process to allow subspecialty recognition. Certification through the FPD process is available only to ABEM diplomates who have advanced training or expertise in emergency ultrasound. Details on the process and requirements are available at [www.ABEM.org](http://www.ABEM.org). The lack of achieving AEMUS FPD does not imply a lack of skill in ultrasound and FPD should not be viewed as required for use of ultrasound by EM graduates or as a requirement for billing for ultrasound.

### **Section 6 – Quality and US Management**

To ensure quality, facilitate education, and satisfy credentialing pathways, a plan for an EUS quality improvement (QI) process should be in place. This plan should be integrated into ED operations. The facets of such a program are listed below. Programs should strive for meeting these criteria and may seek accreditation through the Clinical Ultrasound Accreditation Program (CUAP).

#### ***Emergency US Director***

The emergency US director is a board-eligible or -certified emergency physician who has been given administrative oversight over the EUS program from the EM Chairperson, director or group. This may be a single or group of physicians, depending on size, location(s), and coverage of the group. Specific responsibilities of an US director and associates may include:

- Maintaining compliance with overall program goals: educational, clinical, financial, and academic.
- Selecting appropriate US machines, probes and equipment for the clinical care setting.
- Providing a maintenance care plan to ensure quality, cleanliness, disinfection and storage.
- Overseeing credentialing and privileging for physicians, physician assistants, nurse practitioners, and other healthcare workers within the group and/or academic facility.
- Providing educational resources for physicians, physician assistants, nurse practitioners, and other healthcare workers seeking credentialing, which may include in-house and/or outsourced educational content.
- Monitoring and ensuring documentation of individual physician privileges, educational experiences, and US scans performed.
- Developing, maintaining, and improving an adequate QA process in which physician scans are reviewed for quality in a timely manner and from which feedback is generated.

The emergency US director must be credentialed as an emergency physician and maintain privileges for EUS applications. If less than two years in the position of US director, it is recommended that the director have either: 1) graduated from an EUS fellowship either EUFAC or non-EUFAC accredited, 2) participated in an EUS management course, or 3) completed an EUS preceptorship or mini-fellowship. For ABEM-boarded directors, obtaining and maintenance of the Focused Practice Designation in Advanced EM Ultrasonography is strongly encouraged.<sup>71</sup>

#### ***Supervision of US Training and Examinations***

Ultrasound programs involved in training must have clearly written policies regarding educational US examinations relevant to each type of learner. (See Sections 2, 3, and 4)

### ***US Documentation***

Emergency US is different from consultative US in other specialties as the emergency physician not only performs but also interprets the US examination. In a typical hospital ED practice, US findings are immediately interpreted, and should be communicated to other physicians and services through reports in the electronic medical record (EMR). Emergency US documentation reflects the nature of the exam, which is focused, goal-directed, and performed at the bedside contemporaneously with clinical care. This documentation may be preliminary and brief in a manner reflecting the presence or absence of the relevant findings. Documentation, as dictated by regulatory and payor entities, may require more extensive reporting including indication, technique, findings, and impression. US reports should be available in a timely manner to allow review by members of the health care team and consultants.<sup>77</sup>

During out-of-hospital, remote, disaster, and other scenarios, US findings may be communicated by other methods within the setting constraints. Incidental findings should be communicated to the patient or follow-up clinician. Discharge instructions should reflect any specific issues regarding US findings in the context of the ED diagnosis. Hard copy (paper, film, video) or digital US images should be saved within the ED or hospital archival systems. Digital archival with corresponding documentation is optimal and recommended.<sup>78</sup> Finally, documentation of emergency US procedures should result in appropriate reimbursement for services provided.<sup>9,79</sup> (See Section 7 – Value and Reimbursement)

### ***Quality Improvement Process***

A QI process is an essential part of any US program and should include a QA component focused on review of each clinician's use of ultrasound. QA should evaluate use of ultrasound in indicated clinical scenarios, technical competence for image acquisition and accurate interpretation. Technical parameters to be evaluated might include image resolution, anatomic definition, and other image quality acquisition aspects such as gain, depth, orientation, and focus. In addition, QA should compare the impression from the EUS interpretation to patient outcome measures such as consultative US, other imaging modalities, surgical procedures, pathology reports or patient clinical outcome.

The QI system design should strive to provide timely feedback to physicians. Any system design should have a data storage component that enables data and image recall. A process for patient callback should be in place and may be incorporated into the ED's process for calling patients back. Callbacks should occur when the initial image interpretation, upon QA review, may have been questionable or inappropriate and of clinical significance. In all cases, the imaging physician is informed of the callback and appropriate counseling/training is provided. All studies obtained by non-credentialed physicians should be reviewed.

Once clinicians are credentialed, programs should strive to sample a significant number of studies from each clinician that ensures continued competency. Due to the varieties of practice settings the percentage of studies undergoing review should be determined by the US director and should strive to protect patient safety and maintain competency. While this number can vary, a goal of 5-10% may be reasonable, adjusted for the experience of the clinician and novelty of the US application in that department.

The general data flow in the QA system is as follows:

1. Images obtained by the imaging clinician should be archived, ideally on a digital system. These images may be still images or video clips and should be representative of the US findings.
2. Clinical indications and US interpretations should be documented.
3. These images and data are then reviewed by the US director or a designee.
4. Reviewers evaluate images for accuracy and technical quality and submit the reviews back to the imaging clinician.

5. EUS studies are archived and available for future review should they be needed.

QA systems currently in place range from thermal images and logbooks to complete digital solutions. Finding the system that works best for each institution will depend on multiple factors, such as machine type, administrative and financial support, and physician compliance. Current digital management systems offer significant advantages to QA workflow and archiving.

US QA may also contribute to the ED's local and national QI processes. US QA activities may be included in professional practice evaluation, practice performance, and other quality improvement activities. Measures such as performance of a FAST exam in high acuity trauma, detection of pregnancy location, and use of US for internal jugular vein central line cannulation are examples of logical elements in an overall quality plan. In addition, US QA databases may contribute to a registry regarding patient care and clinical outcomes.

### ***US Machines, Safety, and Maintenance***

Dedicated US machines located in the ED for use at all times by emergency physicians are essential. Machines should be chosen to handle the rigors of the multi-user, multi-location practice environment of the ED.<sup>80</sup> Other issues that should be addressed regarding emergency US equipment include: regular in-service of personnel using the equipment and appropriate transducer care, stocking and storage of supplies, adequate cleaning of external and internal transducers with respect to infection control, maintenance of US machines by clinical engineering or a designated maintenance team, and efficient communication of equipment issues. Clinicians using ultrasound should follow common ED US safety practices including ALARA (as low as reasonably achievable), probe decontamination, and machine maintenance. A policy should be in place to address the use of non-dedicated US machines used by emergency medicine clinicians in the department, such as personal handheld ultrasound devices.<sup>81</sup>

### ***Risk Management***

US can be an excellent risk reduction tool through 1) increasing diagnostic certainty, 2) shortening time to definitive therapy, and 3) decreasing complications from procedures. An important step to managing risk is ensuring that physicians are properly trained and credentialed according to national guidelines such as those set by ACEP and outlined in this document. Proper quality assurance and improvement programs should be in place to identify and correct substandard practice. The greatest risk regarding EUS is lack of its use in appropriate cases.<sup>82</sup>

The standard of care for emergency US is the performance and interpretation of US by a credentialed emergency physician within the limits of the clinical scenario. Physicians performing US imaging in other specialties or in different settings have different goals, scopes of practice, and documentation requirements, and consequently should not be compared to EUS. As EUS is a standard emergency medicine procedure, it is included in any definition of the practice of emergency medicine with regards to insurance and risk management.

### **Section 7 – Value and Reimbursement**

Value in health care has been defined as outcomes that matter to patients relative to cost.<sup>83</sup> The value of CUS is maximized when time spent by the clinician prevents costly imaging, invasive therapeutics, unnecessary consultations and produces accessible real-time results for the patient and the health care system.

Clinical US contributes to patient health in several ways:

1. Improving patient safety by reducing medical errors during procedures

2. Increasing patient satisfaction
3. Improving departmental resource utilization
4. Eliminating costly or invasive procedures
5. Improved clinical decision making

Reimbursement for US derives from Current Procedural Terminology (CPT) codes and their respective relative value units (RVUs). The reimbursements for US are calculated on work performed by entities within the healthcare system, with some going to physicians and some going to hospital entities.<sup>9</sup> The current system assumes a similar workflow for all US. The evolution of CUS has changed the workflow for many clinicians.

From a practical standpoint, reimbursement from the performance of CUS occurs through two primary mechanisms. One is billing for services rendered using Centers for Medicare and Medicaid Services (CMS) guidelines, or direct billing. This is the way that most specialties get reimbursed for performing and interpreting ultrasound and the rules are the same regardless of the specialty. Billing for ultrasound involves the use of CPT codes that define the type of ultrasound performed and ICD-10 codes to support the reason for the ultrasound. Billing for the performance and interpretation of CUS involves following rules determined by CMS, as well as any applicable hospital or third-party rules on performance and documentation of CUS.

The second way for reimbursement of CUS in the ED is within the CMS rules for general ED department visits using the CMS chart leveling process. This is called evaluation and management (E&M) leveling. Charts are coded as level 1 through level 5 with higher levels receiving greater reimbursement. Clinical ultrasound use contributes to the chart leveling process by demonstrating increased complexity and medical decision making by the treating clinician. A percentage of instances when a CUS is performed will result in the visit being eligible for higher chart coding and subsequently higher reimbursement. Stated another way, some patients imaged with ultrasound will have a higher chart level (and reimbursement) when compared to an identical patient who did not receive a clinical ultrasound.<sup>84,85</sup> CMS Requirements such as documentation detail and image retention for billing for clinical ultrasound performance and interpretation do not necessarily apply for revenue obtained through E&M, but hospital or departmental policies would still apply.

The current workflow for CUS differs widely from the historical workflow in traditional imaging specialties. While consultative US centers on providing a work product for the interpreting physician, CUS centers on the patient. The clinician evaluating the patient utilizes US at the patient's bedside to answer a focused question or guide an invasive procedure. The bedside physician takes over tasks that are attributed to the hospital's practice expenses, such as bringing the unit to the bedside, obtaining US images, and archiving images for the medical record. Figure 3 shows the workflow in the model of CUS.

In addition to workflow differences, CUS has generally lower expenses related to capital equipment, physical plant and supplies. The US machine is a less expensive mobile unit located in the ED and moved to the patient's bedside. Some hospitals are turning to lower cost archiving alternatives to PACS, including US management systems (also known as middleware or workflow solutions) or cloud-based software solutions which can allow readily accessible digitally archived images.

CPT values physician work (ie, wRVU) required for common EUS at approximately 40% of the global RVU (total professional plus total technical). Active CUS programs allow the hospital to bill technical fees which support the cost of the machine, supplies, and archiving/quality assurance software.

Efficiencies gained by incorporating US imaging in the care of emergency medicine patients can produce an overall cost savings to the healthcare system. Clinical ultrasound may provide significant benefits by reducing the needs for hospitalization, improved diagnosis and improved outcomes. With these benefits, shared savings should be attributed appropriately to the entity which affected the change.

A more detailed calculation of work depends on the specific clinical system organization and division of labor/resources. Future alternative payment structures such as value-based purchasing, bundled payments, or accountable care organizations (ACOs) should appropriately factor the resources, efficiency and value of CUS into the value and reimbursement of emergency medical care.

### **Section 8 - Clinical US Leadership in Healthcare Systems**

Many specialties in addition to EM utilize CUS across diverse patient care settings. Consequently, there is a need for direction, leadership, and administrative oversight for hospital systems and health systems to support, oversee, and administer an US workflow and due process in an organized, coordinated, and consistent manner. Emergency physicians have decades of experience developing, maintaining, and administering CUS programs within the ED. Furthermore, they have a broad scope of practice and interact with essentially all specialties. Thus, they are uniquely positioned to serve in the role of Systemwide Clinical US Director. Specifically, hospital and healthcare systems should:

- 1) consider CUS separate from consultative imaging and
- 2) use these guidelines and associated guidelines to design institutional clinical US programs; and
- 3) strongly consider experienced emergency physician US leaders for system leadership roles in CUS.

There are many approaches to institutional oversight of multidisciplinary CUS programs including and not limited to: 1) consensus from major utilizers; 2) formation of a governing body such as a CUS steering committee; or 3) creation of the position of an institutional CUS director. This person should have a broad understanding of all applications and integration of CUS. Specific items to consider which require leadership and coordination include policy development, equipment purchase, training and education, competency assessment and credentialing, quality assurance, and value/reimbursement.

As the field continues to grow, there will be an increasingly large number of requests for CUS equipment. There may be advantages to standardizing or coordinating hardware and software when possible so that clinicians may share equipment across departments. This standardization may allow purchasing and cost saving advantages due to bulk purchase negotiations as well as benefits for training with regard to machine familiarity. Standardization may have some negative effects due to vendor exclusivity limiting access to certain advancement in technologies and feature availability only available on other US products.

In academic and community centers there will be a need for educating trainees of different disciplines, specialties, and levels of experience. Ideally, education for each individual specialty should come from within that specialty. In the situation where education is needed and there are no leaders within a specific specialty, then the training may fall to the director or committee as described above. In these cases, the director should work with the leadership within the specialty to meet the training needs of that department. "Train the trainer" programs are encouraged to help build intradepartmental capabilities.

It is crucial to develop subject matter experts within the hospital to meet the ever-increasing administrative, clinical, and educational needs. Once these leaders are established, it will be useful to have the committee and director oversee and coordinate to make sure these pillars are consistent across specialties, and that resources and work effort are shared and not duplicated.

Credentials for each specialty should follow national guidelines and be specialty specific.<sup>72</sup> However, if national training guidelines for specialties do not exist, the director and/or committee should create general credentialing guidelines based on the ACEP structure. These should be flexible enough to meet the needs of that specialty for their relevant applications.



Quality assurance and quality improvement should be organized and run within a department. There may not be subject matter experts with the time, qualifications, and/or interest in providing this workflow requirement. In these cases, the director and/or committee should work with that department/specialty to develop a plan to meet this need. Institutions must provide appropriate resources to system-wide programs. A CUS program can be organized and structured by following the steps outlined in the ACEP System-Wide Ultrasound Director committee documents.<sup>69,86</sup>

## **Section 9 - Future Issues**

Recent technological advances and miniaturization of US devices have improved access and overall US imaging. Wireless transducers, handheld systems and app-based imaging connected via smart device are all becoming the reality of CUS.<sup>87-91</sup> These enhancements represent novel and exciting forms of US technology that expand the availability of US to new clinical settings due to increased portability and relative affordability. These new devices are currently being evaluated in a variety of clinical settings and more diverse situations that had not previously been possible.

While the benefits of handheld US devices are undeniable, concerns regarding operator qualifications, device security, cloud storage, data ownership, disinfection protocols, reimbursement, patient confidentiality, and safety are all serious concerns which continue to persist.<sup>92,93</sup> Non-CUS organizations have raised many of these as potential risks to patient care when not properly addressed.<sup>94</sup> Though there are barriers surrounding handheld US device use, many of these can be overcome by adhering to policies and guidelines developed by organizations such as ACEP to maintain quality and ensure patient safety.<sup>81</sup>

Transducer technology will continue to evolve, including high-resolution transducers that optimize sonographic windows, integrated probe/machine devices, and devices that use existing and new computer connections. Continuous advancements will allow clinicians to utilize US technology increasingly and reduce inherent limitations and obstacles to use. However, cost remains one of most prominent barriers for widespread use of some of the newer and potentially helpful technologies, such as electronic volumetric transducers which allow the acquisition of a large volume of data with no movement of parts within the probe. Currently, there is considerable variation with US workflow and standards; however, the number of vendors in this space has fortunately increased significantly with several hardware manufacturers developing their own workflow and image archiving solutions. The few long-established software-only solutions have been joined by new third-party workflow and archiving vendors, offering more options to CUS users than ever before.

The automation and integration of machine learning into CUS is yet another developing arena. Artificial intelligence (AI) has the potential to dramatically increase the impact of CUS on patient care by assisting with both image acquisition and interpretation. Multiple companies have developed a variety of machine learning algorithms ranging from detection of B-lines on lung US, determination of left ventricular ejection fraction, and enhanced visualization for needle guidance during procedures. The near future holds promise for expanded cardiac assessment capabilities based on additional machine learning algorithms as well as abdominal and musculoskeletal applications. While the progress of AI assistance in CUS has been much slower than initially anticipated, the sheer volume of small and large vendors endeavoring to develop clinically impactful applications will result in a significant expansion of AI-based tools available to CUS users. Many CUS-focused vendors have realized that AI applications must provide customer solutions from start to finish and now incorporate image guidance to locate the target window of interest and then perform an automated assessment of anatomy or function. In the mid and long term, it is anticipated that AI applications will be able to perform rapid and accurate ultrasound assessments more efficiently than humans. Such changes, if realized, will drive down the skill level required to perform ultrasound in a clinically meaningful way. However, the expansion and increased sophistication of machine learning algorithms in

CUS will risk an erosion of skills required to perform ever more complex ultrasound examinations. Patient performed automated ultrasound is on the FDA radar and applications have already been submitted by vendors for clearance. Unsupervised scanning by patients, or consumer-based automated ultrasound may follow.

The implementation of new technologies has played a consistent and central role throughout the history of medical malpractice. Although the evidence is sparse for CUS resulting in increased malpractice claims and some published articles suggest the opposite, we should expect an increase in claims with an increase in utilization. One only has to look to our radiology and obstetrical colleagues to realize that ultrasound related claims will occur with some regularity and anecdotal evidence of more recent malpractice case filings indicates plaintiff attorneys are beginning to target emergency physicians (both for failing to use and for using ultrasound) more than previously seen.

Despite the proliferation of technology, the use of CUS is growing more slowly in non-academic practice settings. Most of the evidence published to date originated from academic settings and more attention needs to be paid in community practice settings, which represent the majority of patients seen globally. To have a meaningful and widespread impact on patient care, it is crucial to integrate CUS into clinical practice outside of academic settings. Physicians in these settings may not even be aware of benefits of ultrasound technology including increased patient safety, improved workflow, and patient throughput as well as the expansion of the examinations available to patients presenting to the ED. Unfortunately, the current community practice dominance by contract groups, which have little incentive to support expansion of emergency ultrasound use, means change will likely continue to occur slowly in those settings.

Telesonography is a rapidly developing model which allows transfer of US images and video from remote locations to obtain consultation and treatment recommendations.<sup>95</sup> Recent advances in US technology, informatics, cloud computing, and 5G networks can allow remote experts to direct on-site, less-experienced sonographers to obtain and interpret images that can impact patient care in real-time. An expert CUS mentor could potentially guide distant untrained health care workers geographically dispersed over multiple locations around the world. This paradigm may be utilized across all applications including procedural assistance. The practice of remote telesonography has the potential to improve quality of care in underserved communities in both domestic and global settings. This is still a growing area with unclear reimbursement policies for emergency medicine physicians that needs further guidance from CMS.

Physician assistants, nurse practitioners, nurses, emergency medical service personnel and others recognize the potential in their practice settings and desire to learn appropriate applications. Emergency physicians should continue to collaborate with our colleagues at local, regional and national levels to help educate and implement appropriate training and practice standards for the safety of our patients. In addition, leadership, supervision, and collaboration with physicians in other specialties will continue to be critical to assure the safe, effective use of CUS.

Importantly, ultrasound should not be conceptualized as an extension of the physical examination. While this was initially seen as a method to deflect criticism and breakdown resistance by some clinical specialties, it is now more commonly utilized to advocate against appropriate reimbursement for a focused diagnostic ultrasound examination at the point-of-care. This approach has already shown evidence of undermining reimbursement and is likely to continue to do so, resulting in many of our current applications being unreimbursed in the future, resulting in limitations in program resources, program expansion, and patient access to care. Emergency physicians should continue to reinforce that CUS is a diagnostic modality, separate from and far above the capabilities of the physical examination and reimbursement is fully indicated.

Finally, quality programs such as the Clinical Ultrasound Accreditation Program<sup>96</sup> will provide leadership to EDs who can meet the criteria in this document. As CUS moves forward, continued high quality research in

the field needs to occur. Future methodological improvements focused on patient outcomes are crucial for the advancement of CUS within medicine. Multi-center studies producing higher levels of evidence will allow the continued growth of CUS in emergency care. The future, while undeniably bright, still requires much effort on the part of us all.

### **Section 10 – Conclusion**

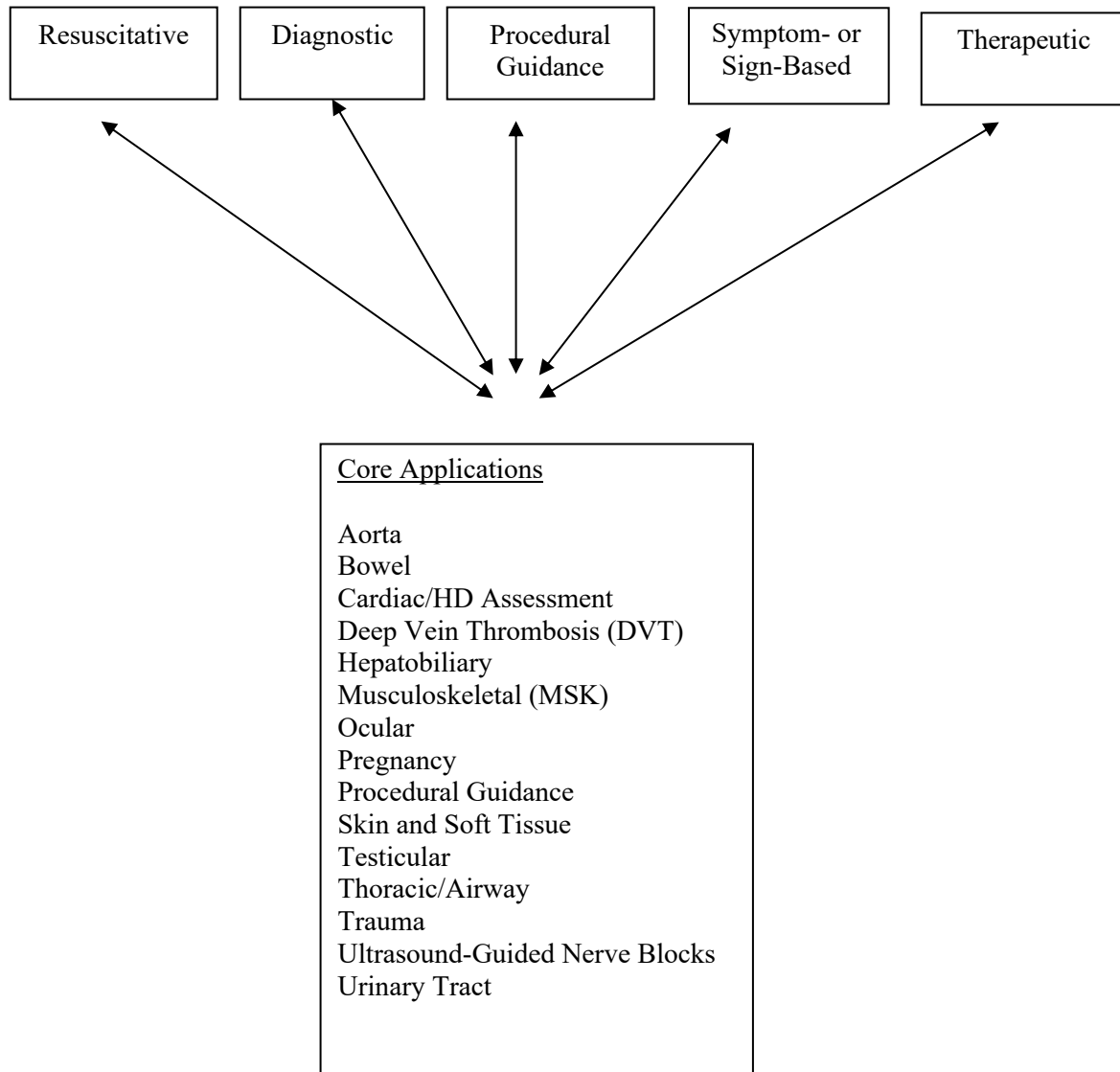
ACEP endorses the following statements on the use of emergency, clinical, point-of-care US:

1. Emergency, clinical point-of-care ultrasound performed, interpreted, and integrated into clinical care by emergency physicians is a fundamental skill in the practice of emergency medicine.
2. The scope of practice of emergency US can be classified into categories of resuscitation, diagnostic, symptom or sign-based, procedural guidance, and monitoring/therapeutics in which a variety of emergency US applications exists, including the core applications of Aorta, Bowel, Cardiac/Hemodynamic Assessment, Deep Venous Thrombosis (DVT), trauma, Hepatobiliary, Musculoskeletal (MSK), Ocular, Pregnancy, Procedural Guidance, Skin and soft-tissue, Testicular, Thoracic/Airway, Trauma, Ultrasound-Guided Nerve Blocks, and Urinary Tract.
3. Training and proficiency requirements should include didactic, experiential and integrative components as described within this document.
4. Emergency US training in EM residency programs should be fully integrated into the curriculum and patient care experience.
5. Emergency US should be considered a core credential for emergency physicians undergoing privileging in modern healthcare systems without need for external certification.
6. US QA and management require appropriate resources including physician direction, dedicated US machines, digital US management systems, and resources for QA.
7. Healthcare clinical point-of-care ultrasound programs optimally led by emergency physicians should be supported with resources for leadership, quality improvement, training, hardware and software acquisition and maintenance.
8. Emergency US is an independent procedure that should be reimbursed and valued, independent of the ED history, physical examination, and medical decision-making.
9. Emergency physicians with advanced US expertise should contribute leadership in clinical ultrasonography at the departmental, institutional, system, national, and international level.
10. Evolving technological, educational, and practice advancements may provide new approaches, efficiencies, and modalities in the care of the emergent patient.

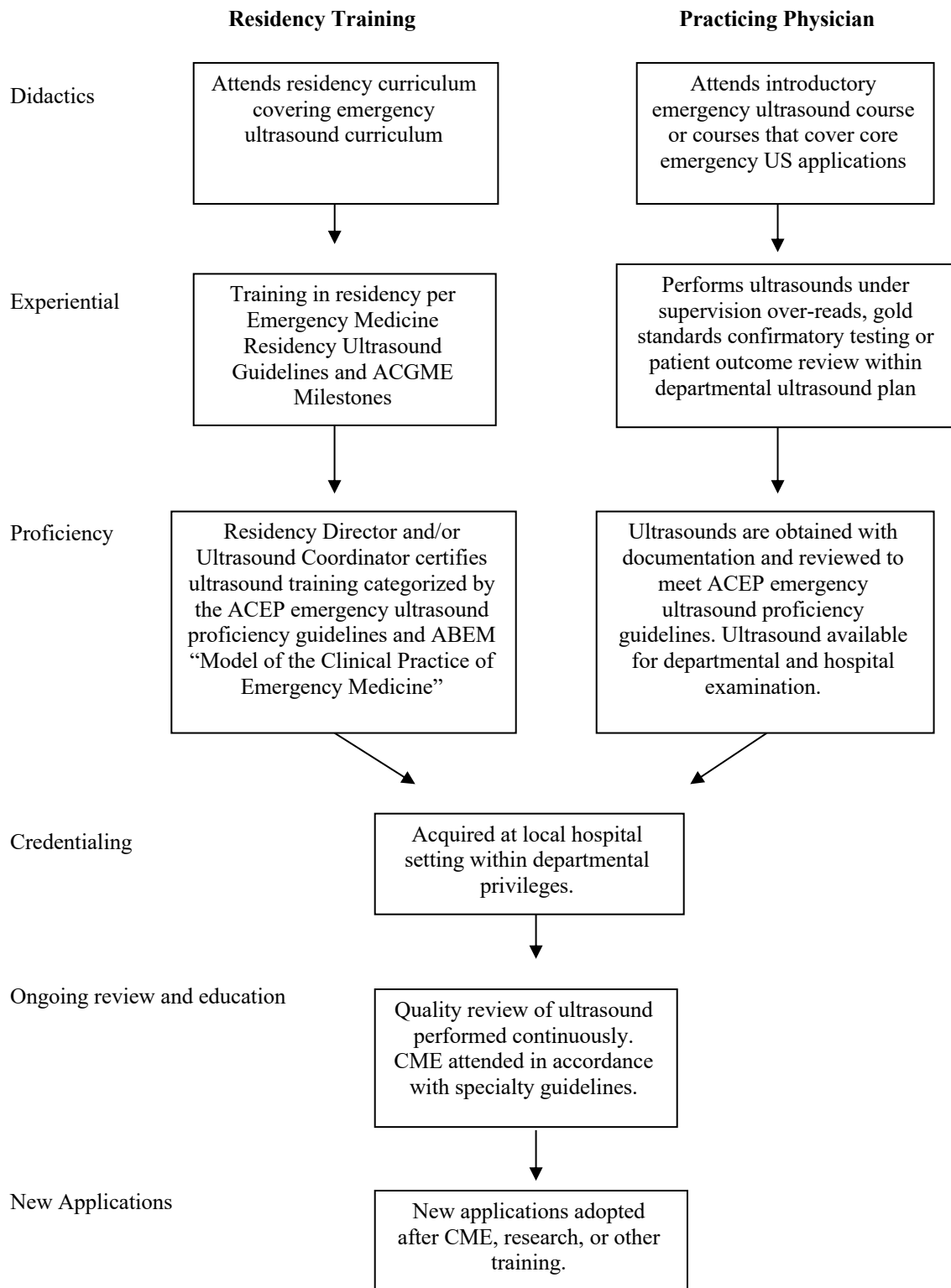
**Table 1. Emergency Medicine Ultrasound Definitions**

Advanced Emergency Medicine Ultrasonography (AEMUS)	US by emergency physicians with advanced training. This term is used by the American Board of Emergency Medicine Focused Practice Designation.
Focused Practice Designation (FPD)	A pathway created by American Board of Medicine Specialties to recognize advanced training. The pathway is specialty specific and applies to advanced knowledge in an area. The American Board of Emergency Medicine offers an FPD in AEMUS.
Point-of-care Ultrasound (POCUS)	US performed by clinicians at the patient’s bedside that answers a specific clinical question. There are many somewhat synonymous terms for US performed by EM physicians at the patient’s bedside.
Emergency Ultrasound	US performed and interpreted by the clinician as an emergency procedure and directly integrated into the care of the patient. There are many somewhat synonymous terms for US performed by EM physicians at the patient’s bedside.
Educational Ultrasound	US performed on a patient, volunteer, or in simulation that is not intended to provide information to further the clinical care of that individual.
Consultative Ultrasound	US performed by non-EM specialists at the request of an EM physician. This US is generally distinct from emergency ultrasound in its scope (less narrow) and purpose (diagnostic question that can wait for a consultant).
Resuscitative Ultrasound	US use directly related to cardiac resuscitation (ACLS), general medical resuscitation (eg, sepsis), or resuscitation from unknown causes.
Diagnostic Ultrasound	US use in a diagnostic imaging capacity. Some diagnostic US are performed in series to monitor physiologic changes.
Sign- or Symptom-Based Ultrasound	US used in a clinical pathway based upon the patient’s symptoms or signs (eg, shortness of breath)
Therapeutic Ultrasound	US use as part of therapy for patient care
Ultrasound-Guided Procedure	US to guide a procedure in real-time
Ultrasound-Assisted Procedure	US used to assist with a procedure that is not performed in real-time (eg, pre-procedural identification)
Limited Ultrasound	US imaging of an organ or organ system that is not comprehensive. This term is used to represent a level of US for coding and billing. Limited US are sometimes confused for incomplete US where a complete set of needed images are not recorded or performed.

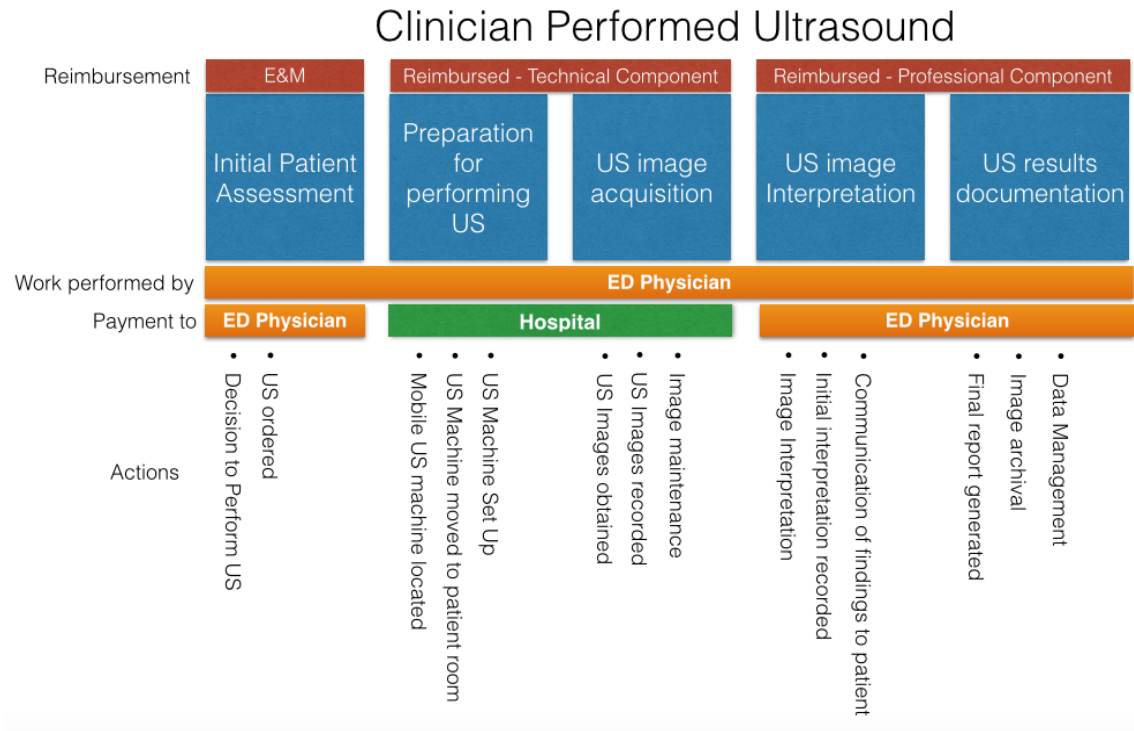
**Figure 1. ACEP 2023 Emergency US Guidelines Scope of Practice**



**Figure 2. Pathways for clinical ultrasound training, credentialing, and incorporation of new applications**



**Figure 3. Clinical Ultrasound Workflow**



## Appendix 1. Evidence for Core Emergency Ultrasound Applications

### Aorta Ultrasound

Clinical ultrasound for aortic evaluation has been primarily focused to identify or exclude the presence or absence of aortic aneurysms. A systematic review assessed the test characteristics of EP-performed US to identify AAA against radiology performed US, MRI, CT, aortography, operative findings or autopsy reports as criterion standards, with pooled data demonstrating sensitivity 97-100%, specificity 94-100%, positive likelihood ratio of 10.8 to infinite, and negative likelihood ratio of 0-0.025 in detecting AAA<sup>97</sup> by EPs. Another study evaluated student-performed ultrasound and was found to be superior to physical exams performed by vascular surgery attendings in detecting AAAs,<sup>98</sup> thus US is a useful tool in detecting AAA, even when performed by less experienced operators. The Screening for Abdominal Aortic Aneurysms Very Efficiently (SAAVE) initiative by Medicare underscores the importance of AAA screening in certain populations and has been shown to decrease AAA-related mortality and rupture,<sup>99</sup> but such screenings were less successful in the busy emergency department setting.<sup>100</sup>

While AAA is the most common aortic pathology seen on US, dissection and rupture are sometimes encountered. In a prospective study, abdominal aortic dissection was identified on EP-performed ultrasound, compared to CT angiography as the criterion standard, with sensitivity of 86%, specificity of 100%, and negative predictive value 84%.<sup>101</sup> Typically rupture is difficult to discern on US, but some signs have been proposed as highly specific for rupture, including irregularity of the aneurysmal shape, focal discontinuity of the aortic wall, floating thrombus, interruption of the thrombus, para-aortic hypoechoic foci, as well as concomitant peritoneal and/or retroperitoneal fluid.<sup>102</sup> When Type A aortic dissections are considered, indirect signs such as, pericardial effusion, aortic regurgitation, and a dilated aortic root can also be identified with bedside cardiac ultrasonography which may increase the sensitivity of this diagnosis.<sup>103-105</sup> However, failure to identify these indirect signs cannot effectively rule out aortic dissection and may occasionally warrant additional diagnostic modalities in the appropriate clinical scenario.<sup>105</sup>

### Bowel

Ultrasound has been studied extensively in the diagnosis of appendicitis for adults and children, with one systematic review and meta-analysis demonstrating that POCUS has a sensitivity of 92% and a specificity of 96%.<sup>2</sup> Ultrasound is considered the first-line diagnostic study for appendicitis in children due to its lack of ionizing radiation compared to CT and availability compared to MRI.<sup>106</sup> It has been demonstrated to decrease CT scan utilization and shorten ED length of stay for children with suspected appendicitis.<sup>107</sup>

Clinical ultrasound can also be utilized to assess for small bowel obstruction, diverticulitis, hernia, and pneumoperitoneum. A large systematic review and meta-analysis found that US was 92.4% sensitive and 96.6% specific for diagnosing small bowel obstruction.<sup>108</sup> Among patients with suspected small bowel obstruction, POCUS is more accurate than x-ray and one study found that US was 3 hours and 42 minutes faster than CT.<sup>109</sup> Ultrasound has been demonstrated to be 92% sensitive and 90% specific for diverticulitis with accuracy approaching that of CT.<sup>110</sup> A recent prospective observational study of emergency medicine clinicians reported that US was 92% sensitive and 97% specific for diverticulitis,<sup>111</sup> while another study found that integrating US into the clinical assessment reduced time to diagnosis by 3 hours and 53 minutes.<sup>112</sup> Ultrasound can identify pneumoperitoneum faster than CT and with greater accuracy than x-ray.<sup>113</sup> A 2018 systematic review and meta-analysis found that US was 91% sensitive and 96% specific.<sup>114</sup> Further, US can provide information about abdominal wall masses and suspected hernias, with 97% sensitivity and 85% specificity,<sup>115</sup> even guiding diagnosis and reduction of hernias at the bedside in real-time.<sup>116</sup>



Among pediatric patients, evidence has been growing regarding the role of clinical ultrasound to identify intussusception and hypertrophic pyloric stenosis. Intussusception is a common cause of pediatric bowel obstruction and can be challenging to diagnose based on history and physical examination alone. Recent data suggest POCUS for intussusception has comparable diagnostic accuracy to radiology-performed studies,<sup>117</sup> and a recent systematic review and meta-analysis reported a sensitivity of 94.9% and a specificity of 99.1%.<sup>118</sup> POCUS for intussusception can also improve time to reduction and shorten ED length-of-stay.<sup>119</sup> While data on POCUS for hypertrophic pyloric stenosis are more limited, recent studies have reported high sensitivity (96.6-100%) and specificity (94-100%),<sup>120,121</sup> as well as decreased length of stay.<sup>121</sup>

### Cardiac and Hemodynamic Assessment

Transthoracic focused cardiac US can be used to assess for pericardial effusion and tamponade, cardiac activity for patients in cardiac or traumatic arrest, global assessment of left ventricular function, right heart strain, and the detection of central venous volume status.<sup>122</sup> EP-performed cardiac US is highly sensitive and specific for the diagnosis of pericardial effusion.<sup>123</sup> In patients with penetrating chest trauma the use of focused cardiac US expedited diagnosis of pericardial fluid and tamponade and lead to expedited treatment.<sup>124</sup> In traumatic and cardiac arrest, US has prognostic value.<sup>125-127</sup> The likelihood of survival is zero after traumatic arrest when either pericardial fluid or cardiac activity are not visualized in cardiac US.<sup>125</sup> In a multicenter study on 793 patients in cardiac arrest, cardiac activity with US was associated with an increased survival to hospital admission (OR 3.6, 2.2-5.9) and hospital discharge (OR 5.7, 1.5-21.9). Although cardiac standstill was associated with mortality, 0.6% patients survived to discharge.<sup>127</sup>

Cardiac US has been incorporated into the management of hypotensive and dyspneic patients. In patients with undifferentiated hypotension, EP-performed cardiac US assessment of left ventricular ejection fraction correlates well with measurements obtained by cardiology,<sup>128</sup> and its use leads to improved diagnostic accuracy for the etiology of hypotension.<sup>129,130</sup> IVC assessment correlates to central venous pressure and can be useful in differentiating different shock states.<sup>131,132</sup> In patients with undifferentiated dyspnea, cardiac US in combination with lung US can differentiate acute heart failure from other etiologies of shortness of breath and guide acute management.<sup>133,134</sup> Based on a systematic review and meta-analysis of 31 studies, US was the single most useful test for diagnosing acute heart failure.<sup>134</sup> Findings of right heart strain on EP-performed cardiac US correlates well with cardiology interpretation.<sup>135</sup> In patients with pulmonary embolism, cardiac US used for the detection of right heart strain is specific and can be used to risk stratify patients.<sup>136-138</sup>

### Deep Vein Thrombosis

Over the past 21 years several studies including systematic reviews and meta-analysis have been performed regarding emergency physician performed limited venous compression sonography for the evaluation of DVT. The overall congruity on the limited compression ultrasound in the evaluation of DVT consistently demonstrated a pooled sensitivity between 90–95% and specificity between 91–98%.<sup>139-141</sup>

In 2018, a multidisciplinary panel of experts convened at the Society of Radiologists Ultrasound Consensus Conference to provide recommendations for the most appropriate point-of-care study for the diagnosis of DVT ultrasound.<sup>142</sup> The consensus from the conference deemed the extended compression ultrasound (ECUS) also referred to as the 3-point compression ultrasound to be the most appropriate point-of-care examination for the diagnosis of DVT.<sup>142,143</sup> The ECUS has also been compared to the 2-point compression ultrasound (2-CUS) which does not include evaluation of the isolated femoral vein. Despite the recommendations from conference, a meta-analysis performed by Lee et al. demonstrated that 2-point and 3-point POCUS were both excellent methods for the diagnosis of DVT with similar sensitivity and specificity in various settings with a multitude of performers.<sup>141</sup> The pitfall to the 2-CUS, however, has been reported to miss 5% to 7% of isolated femoral vein thrombosis.<sup>144-146</sup>

The advantages for using POCUS in the evaluation of DVT is that it can be performed immediately at the bedside with a device that is readily available. This has been demonstrated to provide a faster disposition for patients undergoing POCUS for DVT assessment when compared with radiology department DVT assessment (95 vs. 225 minutes).<sup>147</sup>

### Hepatobiliary System

The use of emergency US for hepatobiliary disease has centered on biliary inflammation and biliary obstruction. With the combination of portability, lack of ionizing radiation, and acceptable test characteristics, US is considered the preferred initial imaging modality for patients suspected of having acute cholecystitis.<sup>148</sup> POCUS by emergency physicians facilitates ED patient throughput: A retrospective review of 1252 cases of suspected cholecystitis demonstrated that bedside emergency physician US vs radiology US evaluation decreased length of stay by 7% (22 minutes) overall, and up to 15% (52 minutes) when patients were evaluated during evening or nighttime hours.<sup>149</sup>

POCUS for the diagnosis of acute cholecystitis is operator dependent and the reported sensitivities and specificities in the literature vary widely. Although many sonographic criteria for acute cholecystitis exist (including gallstones, thickened gallbladder wall, pericholecystic fluid, sonographic Murphy's sign, and common bile duct dilatation), gallstones are present in 95-99% of acute cholecystitis cases.<sup>150</sup> The finding of gallstones is quite accessible to the EP using bedside US, and may be placed into the context of an individual patient's clinical presentation to determine if acute cholecystitis is present. The test characteristics for gallstone detection by bedside US are: sensitivity 90-96%, specificity 88-96%, positive predictive value 88-99% and negative predictive value 73-96%.<sup>151-154</sup> In patients without risk factors for acalculous cholecystitis, one study reported the absence of gallstones on POCUS exam performed by emergency physicians effectively rule-out acute cholecystitis, with excellent negative predictive value (100%).<sup>150</sup> A more recent prospective validation study of the Bedside Sonographic Acute Cholecystitis Score (SAC), incorporating patient symptoms as well as physical and sonographic exam findings by emergency physicians with diverse levels of training, reported 100% sensitivity in ruling out acute cholecystitis when the SAC score was <2 and 95.7% when >7.<sup>155</sup>

The measurement and interpretation of common bile duct dilatation (CBD) to assess for complicated obstructive biliary pathology is considered more technically challenging than simply determining the presence or absence of gallstones. However, one prospective observational study showed that after a focused hepatobiliary training, novice emergency medicine residents attained a moderate level of agreement (Cohen Kappa = 0.79) with expert radiologists in detecting abnormal CBD dilation >6 mm, but only weak agreement in regard to the overall measurements themselves (Cohen's Kappa = 0.45).<sup>156</sup> Additionally, another prospective emergency medicine study demonstrated the sensitivity and specificity of CBD dilation for complicated biliary pathology (CBP) to be only 23.7% and 77.9%, respectively, while none of the 39 patients with CBP had isolated CBD dilation with normal lab values.<sup>157</sup> When the diagnosis of complicated gangrenous cholecystitis is considered, defects of wall enhancement on contrast enhanced ultrasound has been reported to have a sensitivity between 85-91% and a specificity of 67.5-84.8% cholecystitis.<sup>158</sup>

### Musculoskeletal Ultrasound

Clinical ultrasonography is useful for an array of musculoskeletal applications. Clinical ultrasound can be utilized to identify shoulder dislocations and reductions with one recent systematic review and meta-analysis reporting 100% sensitivity and 100% specificity.<sup>3</sup> This same meta-analysis found that POCUS was 96.8% sensitive and 99.7% specific for diagnosing associated fractures.<sup>3</sup> Another study found that POCUS reduced time-to-diagnosis by 43 minutes, while only requiring 19 seconds to perform.<sup>159</sup> Ultrasound can also diagnose joint effusions and guide needle insertion for arthrocentesis or injection.<sup>160</sup> One systematic review and meta-

analysis of knee arthrocentesis found that POCUS increased accuracy (risk ratio 1.21), increased aspiration volume (weighted mean difference [WMD] 17 mL), and had less procedural pain (WMD -2.24/10) with no difference in procedural duration.<sup>161</sup> Another study of emergency medicine residents randomized to ultrasound-guidance versus landmark technique for aspiration of the hip, ankle, and wrist in a cadaver model found that ultrasound guidance had higher success rates (96% vs 89%) and fewer aspiration attempts (median 1 vs 2).<sup>162</sup> For long bone fractures, one systematic review reported that POCUS had 64.7% to 100% sensitivity and 79.2% to 100% specificity in adults.<sup>163</sup> In pediatric patients, POCUS is 93.1% sensitive and 92.9% specific for long bone fractures.<sup>163</sup> If a fracture is present, ultrasound can also be utilized to guide the hematoma block.<sup>164</sup>

Clinical ultrasonography is also valuable for identifying muscle injuries, such as ruptures and tears.<sup>165-168</sup> One study found that ultrasound had similar accuracy to MRI for diagnosing muscular tears.<sup>169</sup> Ultrasound can also be used to diagnose infectious causes of muscle pathology such as myositis and pyomyositis.<sup>170,171</sup> In a retrospective review of 65 cases of surgically-proven pyomyositis, sonographic results were consistent with operative findings in 95% of cases.<sup>172</sup> Clinical ultrasound can be a valuable tool for tendon injuries, as well. In a prospective, multicenter study by Wu et al. Emergency medicine physicians were able to diagnose extremity tendon injuries using POCUS with 100% sensitivity and 95% specificity.<sup>173</sup> There is growing evidence regarding the role of ultrasound for diagnosing tenosynovitis, with one study reporting that ultrasound was 94% sensitive and 65% specific.<sup>174,175</sup>

## Ocular

Ocular ultrasound can be a valuable tool for assessing the posterior segment of the eye, as well as the lens, pupils, and as a surrogate for increased intracranial pressure (ICP). Within the posterior segment, one meta-analysis found that POCUS was 94.2% sensitive and 96.3% specific for retinal detachment.<sup>176</sup> Another large multicenter trial of emergency medicine clinicians reported 96.9% sensitivity and 88.1% specificity for retinal detachment.<sup>177</sup> That study also reported 81.9% sensitivity and 82.3% specificity for vitreous hemorrhage, as well as 42.5% sensitivity and 96.0% specificity for vitreous detachment.<sup>177</sup> Another recent meta-analysis found that POCUS was 100% sensitive and 97% specific for lens dislocation, and 100% sensitive and 99% specific for intraocular foreign body.<sup>178</sup>

Beyond the posterior segment, ocular ultrasound may also be beneficial in the evaluation of patients with eyelid edema or trauma that would otherwise limit inspection of the orbit. Studies have demonstrated the role of ocular ultrasound for the examination of extraocular movement and pupillary assessment.<sup>179</sup> Ultrasound can also be utilized as a non-invasive surrogate for ICP assessment via measurement of the optic nerve sheath diameter (ONSD) with a recent systematic review finding ONSD was 90% sensitive and 85% specific when compared to direct ICP monitoring.<sup>180</sup> Furthermore, ultrasound is 82% sensitive and 76% specific for the detection of optic disc elevation or papilledema which may assist in the identification of long standing elevated ICP seen in patients with idiopathic intracranial hypertension.<sup>181</sup>

## Pregnancy

Emergency ultrasound is used to evaluate the symptomatic pregnant patient and is particularly valuable in the symptomatic first trimester pregnant patient as it is able to provide a definitive diagnosis in 80% of cases.<sup>182</sup> The most common ultrasonographic findings in the first trimester include an indeterminate location of pregnancy, an intrauterine pregnancy, ectopic pregnancy, molar pregnancy, or fetal demise. An ectopic pregnancy is suggested if the endomyometrial mantle (EMM) thickness is less than 8mm, regardless of the Beta-hCG value.<sup>183,184</sup> Identification of ectopic pregnancy in the ED has been shown to expedite care and decrease the time to surgery.<sup>185</sup> In addition, visualization of free fluid in Morison's pouch in patients with suspected ectopic pregnancy can predict the need for operative intervention.<sup>186</sup>

Identification of an intrauterine pregnancy by emergency ultrasound is a powerful rule out test for ectopic pregnancy as supported by evidence from a systematic review and meta-analysis of 2,057 patients which found that emergency ultrasound had a sensitivity of 99.3%, NPV 99.96%, and negative likelihood ratio of 0.08 for ruling out ectopic pregnancy.<sup>187</sup> Emergency ultrasound has also been shown to have high accuracy for dating in the first trimester when compared to radiology ultrasound.<sup>188</sup> In addition, symptomatic first trimester pregnant patients who received a focused emergency ultrasound compared to comprehensive ultrasound had significantly decreased length of stay.<sup>189</sup> In the second and third trimester, emergency ultrasound can be used to evaluate for signs of uterine rupture.<sup>190-192</sup> In the postpartum period, emergency ultrasound can be used to diagnose retained placenta and help to expedite expert consultation and definitive care.<sup>193</sup>

## Procedural Guidance

Ultrasound guidance has been utilized for a wide array of common ED procedures. Ultrasound has been demonstrated to improve success rates and reduce complications for internal jugular, subclavian, and femoral central venous access,<sup>194-196</sup> with the Agency for Healthcare Research and Quality (AHRQ) reporting this as one of the top 11 strategies to increase patient safety in the United States. Similar benefits have been seen with arterial line placement, where US has been shown to increase first-attempt success rates (relative risk [RR] 1.31), reduce number attempts to success (mean difference [MD] -1.26), shorten mean time to success (MD -43.158 seconds), and lower complication rates (RR 0.39).<sup>5</sup> A 2021 meta-analysis comparing US-guided PIV with the landmark-based approach reported that US was associated with greater likelihood of successful cannulation (odds ratio [OR] 2.1), fewer attempts (standardized MD -0.272), and improved patient satisfaction (standardized MD 1.467/10) with no difference in procedural length.<sup>4</sup>

Beyond vascular access, US can be a valuable adjunct for lumbar puncture (LP) with one recent meta-analysis reporting increased overall success (OR 2.22), fewer traumatic LPs (risk difference -16.4%), shorter time to successful LP (adjusted MD -1.80 minutes), fewer mean needle passes (adjusted MD -0.61), and reduced patient pain scores (adjusted MD -2.53/10) in the US group.<sup>6</sup>

The data supporting ultrasound-guided abdominal paracentesis is less robust; however, ultrasound has been shown to improve procedural success and decrease complications. Ultrasound is superior to physical exam for determining the presence of ascites pre-procedure,<sup>197</sup> and using ultrasound-guidance for paracentesis leads to improved success rates compared with the landmark-based approach (95% vs 61%), decreased bleeding complications (OR 0.32) and decreased hospital costs (MD -\$6,262).<sup>198,199</sup> Similarly, ultrasound-guidance for thoracentesis has been demonstrated to reduce complications, with one meta-analysis reporting decreased pneumothorax rates when US was used (OR 0.3).<sup>200,201</sup> One randomized control trial evaluated the use of US in the diagnosis and management of peritonsillar abscess.<sup>202</sup> Patients in the US cohort were successfully aspirated more frequently (LR 2.0), had fewer consults (absolute difference -43%), and more accurate diagnosis (LR 2.8). Finally, ultrasound-guided pericardiocentesis has become the standard within cardiology (rather than a blind technique) based on several large observational trials which demonstrated a high success rate (97-98%) and a low complication rate (4.7-7%).<sup>203,204</sup> Though emergency medicine specific studies are lacking, this supports the role for ultrasound-guidance of pericardiocentesis.

## Skin and Soft Tissue Ultrasound

Point-of-care ultrasound is a valuable tool for the diagnosis and management of skin and soft tissue abscesses. A recent systematic review and meta-analysis found that POCUS was 94.6% sensitive and 85.4% specific for differentiating abscess from cellulitis.<sup>205</sup> Among those with a high pretest probability, POCUS is 93.5% sensitive and 89.1% specific.<sup>205</sup> Among those cases that are clinically unclear, POCUS is significantly more accurate (91.9% sensitivity, 76.9% specificity) compared with physical examination alone (77.6% sensitivity,

61.3% specificity).<sup>205,206</sup> Moreover, the addition of POCUS led to a change in management in 10.3% of cases with a number-needed-to-treat of 10.<sup>205</sup> Once an abscess is suspected, POCUS can identify nearby vasculature and help differentiate it from a pseudoaneurysm using color Doppler.<sup>207</sup> POCUS can also help identify the depth and margins of the abscess to guide the placement of the incision and assess for adequate drainage.<sup>207</sup>

POCUS can also be used for the diagnosis and management of skin and soft tissue foreign bodies. It can detect non-radiopaque foreign bodies that could be missed on standard radiographs with one systematic review reporting that POCUS was 72% sensitive and 92% specific for foreign bodies.<sup>208</sup> It can also be used for real-time guidance of foreign body removal and can assist in detecting surrounding structures.

Finally, clinical ultrasound can help diagnose more dangerous conditions such as necrotizing fasciitis (NF). Although the concern for NF is typically a clinical diagnosis, POCUS can assist in earlier diagnosis, especially in patients who are too unstable for other imaging modalities (eg, CT, MRI). One study found that POCUS was 100% sensitive and 98.2% specific,<sup>209</sup> while another study reported a sensitivity of 88.2% and specificity of 93.3% for the diagnosis of NF.<sup>210</sup> In resource-limited settings without CT or MRI, clinical ultrasound can assist clinicians along with clinical gestalt in the diagnosis of NF. It is also easily repeatable and can be used to evaluate for progression of NF at the bedside.

### Testicular Ultrasound

Ultrasound is the first line diagnostic study in addition to the clinical history and physical exam in the evaluation of the acute scrotum in the ED.<sup>211</sup> Emergent and urgent pathologic etiologies identified via ultrasound include testicular torsion, torsion of the testicular or epididymal appendage, infections of the scrotum, epididymis, and testis, strangulated herniation of abdominal contents into the scrotum, as well as traumatic injuries of the testicle.<sup>211</sup> A recent review recommends grayscale and color Doppler to remain the mainstays of acute scrotal evaluation, while contrast enhanced ultrasound and elastography are new techniques that can improve sensitivity in equivocal cases.<sup>212</sup>

Ultrasound has been found to be highly accurate in the diagnosis of pathology in the patient presenting with acute scrotum in both the adult and pediatric populations.<sup>213,214</sup> Accuracy for adult EPs in evaluation of the acute scrotum have been found to be highly sensitive (95%) and specific (94%) when compared with radiology ultrasound.<sup>215,216</sup> Accuracy for pediatric EPs in evaluation of the acute scrotum have also been found to be highly sensitive, with 100% sensitivity and 99.1% specificity in the diagnosis of testicular torsion.<sup>217</sup> A recent systematic review and meta-analysis indicates that the “whirlpool” sign is pathognomonic in adult patients suspected of having testicular torsion, but less useful in neonatal populations.<sup>218</sup> Clinical ultrasound may be especially useful in patients suspected of Fournier’s gangrene as it has comparable sensitivity with computed tomography and can be performed at the bedside for unstable patients.<sup>219</sup> A review of cases shows that testicular ultrasound is also highly sensitive and specific (100% and 93.% respectively) in the diagnosis of testicular rupture in the testicular trauma.<sup>220</sup>

### Thoracic/Airway

Considerable evidence supports the use of clinical ultrasonography to diagnose a variety of thoracic conditions such as pulmonary edema, pneumonia, pulmonary contusion, and pleural effusion. These conditions can be assessed dynamically over time in response to therapeutic interventions such as diuresis, non-invasive ventilation, and antibiotics. POCUS assessment for B-lines is 83-92% sensitive and 84-92% specific for pulmonary edema and congestive heart failure.<sup>1,221</sup> POCUS is 85-92% sensitive and 93% specific for diagnosing pneumonia,<sup>222,223</sup> including 83-96% sensitivity and 84-93% specificity in children.<sup>224,225</sup> Amidst the global pandemic, thoracic POCUS has demonstrated 91% sensitivity and 63% specificity for COVID-19 in the emergency department.<sup>226</sup> Additionally, POCUS evaluation for a focal B-pattern in patients

with thoracic trauma is 92% sensitive and 89% specific for pulmonary contusion.<sup>227</sup> Lastly, POCUS is 91% sensitive and 92% specific for the diagnosis of pleural effusion.<sup>228</sup> For patients with undifferentiated dyspnea, early performance of POCUS can decrease time to diagnosis and disposition.<sup>229</sup>

Ultrasonography has also been increasingly recognized as a valuable tool for airway assessment and management.<sup>230</sup> Prior to endotracheal intubation, POCUS can be utilized to predict difficulty of intubation, with one study reporting that POCUS outperformed several common clinical decision tools.<sup>231</sup> After an intubation has been performed, one large meta-analysis found that transtracheal ultrasound identified endotracheal versus esophageal intubation with 99% sensitivity and 97% specificity.<sup>232</sup> This accuracy has remained consistent regardless of transducer, technique, or endotracheal tube size.<sup>233,239</sup> Lung sliding can be used as an alternate tool to assess for endotracheal tube location, as well as for endobronchial intubation.<sup>238,239</sup> This has been supported by the American Heart Association guidelines for Advanced Cardiac Life Support, which delineate clinical ultrasonography as a reasonable tool for confirming endotracheal intubation.<sup>240</sup> Finally, ultrasound can be utilized to identify the cricothyroid membrane in advance of a difficult intubation and even guide cricothyroidotomy in patients requiring a surgical airway.<sup>241,243</sup>

## Trauma

The use of US in trauma patients to detect intra-abdominal, intrathoracic, or pericardial hemorrhage has been incorporated in most trauma center protocols and is a part of the ATLS guidelines.<sup>244</sup> A review of 11 prospective studies shows that the focused assessment with sonography in trauma (FAST) examination has sensitivities ranging from 87-98% and specificities 99% -100% in detecting intraperitoneal fluid in patients who suffer from blunt trauma.<sup>245</sup> The evaluation of the thorax for injury with ultrasound defines the extended focused assessment with sonography in trauma (EFAST) examination. The scope of the EFAST includes the detection of pneumothorax, intrathoracic hemorrhage, and/or pulmonary contusions.<sup>246,247</sup> Ultrasound is more sensitive than chest radiograph in detecting a pneumothorax with lung point being a very specific sign, however, delaying management to identify the lung point is not recommended.<sup>248</sup>

The EFAST examination can be used to evaluate penetrating trauma for thoracic and cardiac injuries with high sensitivities for detecting pathology that require acute intervention. A retrospective review of patients with penetrating thoracic trauma demonstrated 100% sensitivity for the detection of pericardial effusion which expedited diagnosis and management.<sup>124</sup> Alternatively, the evaluation for penetrating abdominal trauma may vary by case but evidence demonstrates a low sensitivity therefore making it a limited screening tool.<sup>249</sup>

The use of the EFAST examination in trauma has improved patient care and resource utilization by decreasing the time to operative management, decreasing patient's exposure to ionizing radiation, shortening their length of stay in the hospital, and lowering patient costs.<sup>250, 251</sup>

## Ultrasound Guided Nerve Blocks

Ultrasound-guided peripheral nerve blocks are an important part of a multi-modal approach to pain management in the ED.<sup>252</sup> Nerve block indications have continued to expand, and studies have demonstrated the benefits of EP performed nerve blocks including improved pain control, decreased opioid use, and decreased length of stay, to name a few. Overall safety for nerve blocks is also high, with data suggesting the risk of peripheral nerve injury being as low as 0.03% and local anesthetic systemic toxicity occurring in 1.3 per 10,000 patients.<sup>253,254</sup> The most commonly performed nerve blocks include brachial plexus blocks, truncal blocks, hip blocks and extremity blocks.

Brachial plexus blocks, including the superficial cervical plexus, RAPTIR, interscalene and supraclavicular brachial plexus block, have been used for shoulder dislocation reductions, proximal humerus fractures, elbow, wrist and hand lacerations and fractures. One randomized study demonstrated shorter length of stay using the interscalene brachial plexus block for shoulder dislocation reduction compared to moderate sedation.<sup>255</sup>

Truncal blocks, including the serratus anterior plane block (SAPB), erector spinae plane block (ESP) and transversus abdominis plane block have been used for rib fractures, thoracostomy tube placement, herpes zoster, renal colic, pancreatitis, lumbar transverse process fractures, and mechanical back pain.<sup>256</sup> One RCT showed significant reduction in pain scores up to 24 hours after the block in patients who received a SAPB block compared to a control group receiving tramadol.<sup>257</sup> Studies have found that patients who received ESP for rib fractures had a significant reduction in pain scores<sup>258</sup> and improvement in inspiratory capacity.<sup>256</sup> Another randomized study found that patients with renal colic who received an ESP block compared to those who received an NSAID had significantly better pain control, lower rates of opioid consumption and greater patient satisfaction.<sup>259</sup> Transversus abdominis plane blocks have been used for pain control from post-op hernias, abdominal wall abscesses, and appendicitis.<sup>260,261</sup>

Nerve blocks such as the fascia iliaca, femoral nerve, and pericapsular nerve group block (PENG) are used for pain control for hip fractures. These blocks are an important component of multimodal analgesia that is recommended by the American Academy of Orthopaedic Surgeons<sup>262</sup> and recognized as best practice by the American College of Surgeons.<sup>263</sup> Systematic reviews of multiple randomized controlled studies have found that patients who received a nerve block for hip fracture had reduced pain on movement, decreased rates of delirium and chest infection, and decreased time to mobilization.<sup>264</sup> When performed in the ED, fascia iliaca blocks have been shown to decrease opioid consumption, length of stay, and hospital admission within 30 days of hip fracture.<sup>265,266</sup> In addition, the PENG block has been successfully used to control pain from non-operative pelvic fractures.<sup>267</sup>

Upper extremity forearm blocks and lower extremity blocks such as the popliteal sciatic, tibial, transgluteal sciatic, sural, and adductor canal blocks have been performed for extremity injuries including fractures, burns, abscesses, dislocation reductions, lacerations, and radicular leg pain.<sup>268,269</sup> One small randomized study found that patients with hand injuries randomized to receive forearm nerve blocks had significant reduction in pain compared to the control group who received usual care.<sup>270</sup>

## Urinary Tract

The use of EUS in the urinary tract has primarily been used for detection of hydronephrosis and bladder status but has also been used to evaluate for renal masses, cystic structures, and foley catheter placement. A multispecialty panel with representation from EM, urology, and radiology recommends US evaluation of the patient with suspected renal colic in conjunction with urinalysis in almost all clinical scenarios except for the extreme elderly.<sup>271</sup> Bedside renal US can decrease ED length of stay without increasing patient bounce backs in patients suspected of having renal colic.<sup>272</sup> A large systematic review and meta-analysis of clinical renal US showed a pooled sensitivity of 70.2% and specificity of 75.4%<sup>271,273</sup> for the evaluation of renal colic. When only moderate or severe hydronephrosis were considered, the specificity increased to 94.4%.<sup>271</sup> Accuracy of bedside US by fellowship trained EP is comparable to that of radiology US and CT imaging for imaging patients with suspected renal colic.<sup>274,275</sup> Furthermore, ultrasound evaluation of the patient with renal colic has not shown to miss clinically significant alternate diagnoses in the majority of patients.<sup>271,274,276</sup>

Evidence on evaluation of the bladder primarily focuses on volumetric measurements in the clinical setting. Volumetric measurements of the bladder have been useful especially in pediatric populations where it has shown to improve first pass success of catheterization.<sup>277</sup>

## Appendix 2. Evidence for Advanced Emergency Ultrasound Applications

### Adnexal Pathology

The use of CUS to evaluate pelvic pain in the non-pregnant female may facilitate the diagnosis of adnexal pathology such as ovarian torsion, tubo-ovarian abscess (TOA), and ovarian cysts. The evaluation of the adnexa is an advanced skill that requires appropriate training.<sup>278</sup> Although transabdominal ultrasound may be used to identify these structures, transvaginal ultrasound is the preferred modality to visualize the adnexa. The use of transvaginal ultrasound has been shown to improve physician confidence in the evaluation of nonpregnant women with pelvic pain as compared to a traditional bimanual exam.<sup>279</sup> Ovarian torsion is challenging to diagnose and is often a missed diagnosis in the ED.<sup>280</sup> The use of bedside ultrasound may expedite identifying ovarian cysts, presence of venous and/or arterial blood flow, and an enlarged ovary, which may be an early sign of torsion despite visualizing blood flow.<sup>281</sup> Differentiating pelvic inflammatory disease from TOA is important for management decisions, and the sensitivity of ultrasound for the diagnosis of tubo-ovarian abscess ranges from 56-93%, with specificity ranging from 86%-98%.<sup>282</sup> The use of CUS to rapidly identify TOA may help expedite treatment.<sup>283</sup> Clinical US may also lead to an early diagnosis of rare adnexal conditions such as hyperstimulation syndrome and lead to rapid treatment.<sup>284</sup>

### Advanced Echocardiography

Advanced echocardiography is beneficial in the evaluation of emergency department patients, particularly in the critically ill when basic echocardiography is not definitive. Examples include recognizing early tamponade physiology,<sup>285,286</sup> acute diastolic heart failure,<sup>287,288</sup> acute pulmonary embolism,<sup>289-291</sup> myocardial injury in acute coronary syndrome,<sup>292,293</sup> and hemodynamic states like fluid tolerance and responsiveness.<sup>294,295</sup> These assessments use spectral or tissue Doppler over or near valves, with calculations based on amplitude ratios or flow pattern tracings.

Transthoracic echocardiography during cardiac arrest is another emerging application. Early literature focused on echocardiographic cardiac standstill as a prognostic factor to discontinue resuscitation. However, ultrasonographic determination of cardiac standstill may be difficult,<sup>296</sup> and more attention has been centered around using echocardiography to guide ACLS. Obtaining views before the pulse check pause prevents inadvertent delay over the ten second window.<sup>297</sup> Focusing on views of the left ventricle allows for assessment of CPR compression location and adequacy.<sup>298</sup> Fine ventricular fibrillation or tachycardia appear with subtle tremulous movements of ventricular free walls and valves.<sup>298,299</sup> Visualization of these shockable rhythms is useful as they may not always appear on patient monitors. These concepts are mirrored in emerging transesophageal literature.

### Contrast-Enhanced Ultrasound

Contrast-enhanced ultrasound (CEUS) has several potential applications in the acute care setting.<sup>300</sup> The use of ultrasound contrast agents (UCAs), microbubbles that are injected intravascularly, is FDA approved for use in echocardiography and evaluation of liver lesions in adults, as well as vesicoureteral reflux evaluation in children. UCA use in the evaluation of solid organ injury in blunt abdominal trauma is an off-label application that is well-supported in European literature. In 2009, Catalano et al published a study of 156 patients with blunt abdominal trauma, showing ultrasound contrast improved the sensitivity of identifying renal trauma from 36% to 69%, liver trauma from 68% to 84%, and splenic trauma from 77% to 93%.<sup>301</sup> Specificity of identifying injury improved from 98% to 99% in renal trauma, 97% to 99% in liver trauma, and 96% to 99% in splenic trauma.<sup>301</sup> Serious adverse events occur rarely. In a study of 30,222 patients, 0.02% had an adverse reaction and 2 patients (0.007%) had early signs of anaphylaxis that improved with



treatment.<sup>302</sup> Future possible applications beyond trauma include the evaluation of abdominal aortic aneurysm rupture, sono-thrombolysis, and assessment of tissue perfusion.<sup>303-305</sup>

### Transcranial Doppler

Transcranial Doppler (TCD) through the transtemporal window may be incorporated as an adjunct imaging modality for the neurocritical patient. TCD may be used to evaluate for mass effect causing brain midline shift,<sup>306</sup> vasospasm after subarachnoid hemorrhage (SAH),<sup>307</sup> diagnosis and thrombolytic efficacy in acute ischemic stroke,<sup>308</sup> elevated intracranial pressure,<sup>309</sup> and cerebral circulatory arrest.<sup>310</sup> The presence and extent of midline shift may be assessed by measuring the distance from the ipsilateral temporal bone to the midline third ventricle, and then repeating that measurement from the contralateral temporal bone. After suffering a SAH, vasospasm may be suggested by increased blood flow velocity in the middle cerebral artery (MCA) due to the inverse relationship between cerebral blood vessel diameter and velocity. In the setting of acute ischemic stroke, MCA blood flow velocities may be used to suggest the success or failure of recanalization after thrombolysis. Lastly, detection and dynamic evaluation of elevated intracranial pressure can be examined through the semi-quantitative relationship between systolic and diastolic blood flow velocity as intracranial pressure rises and cerebral perfusion pressure falls. The end-stage flow patterns may serve as an adjunct for determining cerebral circulatory arrest and brain death.

### Transesophageal Echocardiography

With the same goal-directed framework of CUS applications, focused or resuscitative transesophageal echocardiography (TEE) has been increasingly utilized for the evaluation of intubated critically-ill patients. Several observational studies performed in the late 1990s and early 2000s demonstrated the feasibility and clinical impact of TEE to identify reversible pathologies and guide therapies in patients with cardiac arrest and peri-arrest states in the ED,<sup>311</sup> intensive care units,<sup>312,313</sup> and operative settings.<sup>314-7</sup>

Subsequent studies have established that emergency physicians can obtain focused TEE images after a brief structured simulation-based training.<sup>318,319</sup> In addition to the same diagnostic, prognostic, and therapy-guiding role provided by TTE, TEE presents unique advantages in the resuscitative setting, including the ability to obtain high-quality images regardless of body habitus, presence of subcutaneous emphysema, use of mechanical ventilation or ongoing cardiopulmonary resuscitation (CPR). In a retrospective observational study, Arntfield et al reported the successful implementation of a focused ED-TEE program demonstrating that TEE was feasible, safe, and clinically influential.<sup>320</sup> In 78% of the exams performed, there was a diagnostic impact on case management, which was commonly cited as excluding etiologies of cardiac arrest. An analysis based on TEE diagnoses suggested that 55.6% of these exams had findings that could not be easily visualized on TTE.

In a prospective observational study of out-of-hospital cardiac arrest (OHCA) patients, Teran et al found resuscitative TEE could be performed early in the resuscitation, and found TEE to have a diagnostic, therapy-guiding or prognostic impact in 97% of cases. Diagnoses included fine ventricular fibrillation, right ventricular dilation, and the presence of intracardiac thrombus. In addition to the diagnostic applications of resuscitative TEE, this modality offers the unique possibility to visualize the heart during the performance of chest compressions, thus the potential to optimize the quality of CPR. In a prospective ED study, the hand position used during external chest compressions resulted in compression of the left ventricular outflow tract (LVOT) and the aortic root, but not the left ventricle (LV), and found a correlation between the area of maximal compression (AMC) and the stroke volume (SV), where compressions closer to the LV produced higher a SV.<sup>320</sup> Consistent evidence was reported in recent years by Cha et al, Teran et al, and Catena et al.<sup>321-323</sup> Taken together, these studies support the idea that TEE can be used by clinicians to optimize the quality

of chest compressions in real time during CPR, by identifying and correcting compression of the outflow tract, with the potential to improve outcomes.

Studies in the ED setting have also shown that TEE could shorten chest compression interruptions,<sup>324</sup> and guide resuscitative procedures such as guidance of intravenous pacemaker placement,<sup>325</sup> and extracorporeal membrane oxygenation (ECMO).<sup>326,327</sup>

### Appendix 3. Clinical Ultrasound Learning Objectives

Listed below are recommended learning objectives for a comprehensive CUS clinician curriculum, rotation, or series of training courses. For detailed indications, limitations, protocols, documentation requirements, and other important details for each application, please refer to the ACEP Emergency Ultrasound Imaging Criteria Compendium.<sup>12</sup>

#### Introduction

- Distinguish between consultative, clinical, point-of-care, and emergency ultrasound (EUS).
- Recognize primary CUS applications.
- Discuss support for CUS from key organizations including ACEP, AMA, ABEM, SAEM, and AIUM.
- Describe ACEP recommendations on training and credentialing in CUS.

#### Physics & Instrumentation

- Explain ultrasound physics relevant to CUS:
  - Piezoelectric effect
  - Frequency
  - Resolution
  - Attenuation
  - Echogenicity
  - Doppler - color and spectral
  - Aliasing
- Operate the EUS system as needed to obtain and interpret images adequate for clinical decision making including:
  - Knobology
  - Image mode
  - Gain
  - Time gain compensation (TGC)
  - Focus
  - Transducer types
- Recognize common ultrasound artifacts including:
  - Reverberation
  - Side lobe
  - Mirror
  - Shadowing
  - Enhancement
  - Ring-down

#### Trauma (Focused Assessment by Sonography in Trauma (FAST))

- Describe the indications, clinical algorithm, and limitations of CUS in blunt and penetrating thoracoabdominal trauma.
- Perform the CUS protocol for Trauma in both primary and secondary surveys.
- Identify relevant US anatomy including the pleura, diaphragm, inferior vena cava, pericardium, liver, spleen, kidneys, bladder, prostate and uterus.
- Recognize pathologic findings and pitfalls in the evaluation of pneumothorax, hemothorax, pulmonary contusion, hemopericardium, cardiac activity, volume status, and hemoperitoneum.
- Integrate Trauma CUS findings into individual patient, departmental, and disaster management.

#### Female Pelvis

- Transabdominal and/or transvaginal approach

- Basic obstetrical CUS

#### First-Trimester Pregnancy

- Describe the indications, clinical algorithm, and limitations of CUS in first-trimester pregnancy pain and bleeding.
- Understand the utility of quantitative B-HCG in the evaluation of first-trimester pregnancy pain and bleeding.
- Perform CUS protocols for transabdominal and transvaginal views as appropriate, including fetal heart rate and gestational age measurement techniques.
- Identify relevant US anatomy including the cervix, uterus, adnexa, bladder and cul-de-sac.
- Recognize the relevant findings and pitfalls when evaluating for intrauterine and ectopic pregnancy:
  - Early embryonic structures including the gestational sac, yolk sac, fetal pole, and heart
  - Location of embryonic structures in pelvis
  - Embryonic demise
  - Molar pregnancy
  - Findings of ectopic pregnancy including pseudogestational sac, free fluid, and adnexal masses

#### Advanced Evaluation

- Basic gynecological CUS
  - Ovarian cysts, fibroids, tubo-ovarian abscesses
  - Ovarian torsion
  - Ectopic pregnancy
  - 2<sup>nd</sup> and 3<sup>rd</sup> trimester OB
- Integrate pregnancy EUS findings into individual patient and departmental management.

#### Aorta

- Describe indications, clinical algorithm, and limitations of CUS in the evaluation of abdominal and thoracic aortic pathology.
- Perform CUS protocols to evaluate the abdominal and thoracic aorta including measurement techniques.
- Identify relevant US anatomy including the aorta with major branches, inferior vena cava, and vertebral bodies.
- Recognize pathologic findings and pitfalls when evaluating for abdominal and thoracic aortic aneurysm and dissection.
- Integrate Aorta EUS findings into individual patient and departmental management.

#### Cardiac and Hemodynamic Assessment

- Describe the indications and limitations of cardiac CUS.
- Perform standard CUS windows (subcostal, parasternal, and apical) and planes (four chamber, long and short axis).
- Identify relevant US anatomy including pericardium, cardiac chambers, valves, descending aorta and inferior vena cava.
- Estimate qualitative left ventricular function and central venous pressure to guide hemodynamic assessment of patient.
- Recognize cardiac arrest, pericardial effusions with or without tamponade, and dilation of the aortic root or the descending aorta.
- Advanced evaluation
  - Acquire view of the aortic arch and recognize aortic arch dissection and/or aneurysm.
  - Identification of right ventricular dysfunction.
  - Assessment of cardiac output and fluid responsiveness.

- Procedural guidance: pericardiocentesis, transvenous pacer, and central venous catheter placement
- Integrate Emergency echocardiography findings into individual patient and departmental management.

#### Hepatobiliary

- Describe the indications and limitations of CUS of the biliary tract.
- Perform CUS protocols to evaluate the biliary tract.
- Identify relevant ultrasound (US) anatomy including the gallbladder, portal triad, inferior vena cava, and liver.
- Recognize the relevant findings and pitfalls when evaluating for cholelithiasis and cholecystitis.
- Advanced evaluation
  - Common bile duct pathology (dilatation and choledocholithiasis)
  - Liver pathology (masses, pneumobilia, hepatomegaly)
  - Portal vein abnormalities
  - Pancreas pathology
- Integrate EUS of the biliary tract into individual patient and departmental management.

#### Urinary Tract

- Describe the indications and limitations of CUS of the kidneys and bladder.
- Perform CUS protocols to evaluate the urinary tract.
- Identify relevant US anatomy including the renal cortex, renal pelvis, ureter, bladder, liver, spleen, and uterus or prostate.
- Recognize the relevant findings and pitfalls when evaluating for hydronephrosis, renal calculi, renal masses, bladder volume, pregnancy, and Foley catheter evaluation.
- Integrate EUS of the urinary tract into individual patient and departmental management.

#### Deep Vein Thrombosis

- Describe the indications and limitations of CUS for the detection of deep venous thrombosis.
- Understand the differences between lower extremity venous CUS and radiology lab-or vascular lab-performed “Duplex evaluation”
- Perform CUS protocols for the detection of deep venous thrombosis of the upper and lower extremities including:
  - Vessel identification
  - Compression
  - Doppler imaging of respiratory variation and augmentation.
- Identify relevant US anatomy of the upper and lower extremities including the deep venous and arterial systems, major nerves, and lymph nodes.
- Recognize the relevant findings and pitfalls when evaluating for deep venous thrombosis.
- Integrate EUS for deep venous thrombosis into individual patient and departmental management.

#### Skin and Soft Tissue

- Describe the indications and limitations of skin and soft tissue EUS.
- Perform EUS protocols for the evaluation of skin and soft tissue pathology.
- Identify relevant US anatomy including:
  - Skin
  - Adipose
  - Lymph Nodes
- Recognize the relevant findings and pitfalls when evaluating the following:
  - Soft tissue infections: Abscess versus cellulitis
  - Subcutaneous fluid collection identification
  - Foreign body location and removal

Copyright © 2023 American College of Emergency Physicians. All rights reserved.

- Integrate skin and soft tissue EUS findings into individual patient and departmental management.

#### Musculoskeletal

- Describe the indications and limitations of musculoskeletal EUS.
- Perform EUS protocols for the evaluation of musculoskeletal pathology.
- Identify relevant US anatomy including:
  - Tendons and Ligaments
  - Muscles
  - Bones
  - Joints
- Recognize the relevant findings and pitfalls when evaluating the following:
  - Tendon injury (laceration, rupture)
  - Fractures
  - Joint identification
- Integrate musculoskeletal EUS findings into individual patient and departmental management.

#### Thoracic/Airway

- Describe the indications and limitations thoracic CUS
- Perform CUS protocols for the detection of:
  - Pneumothorax
  - Pleural Effusion
  - Interstitial Lung Fluid (CHF, ARDS, pneumonia, pulmonary contusion)
- Identify relevant US anatomy of thoracic structures.
- Recognize the relevant findings and pitfalls when evaluating for thoracic pathology
- Recognize the sonographic findings of tracheal and esophageal anatomy, especially in regard to EM procedures
- Integrate thoracic CUS findings into individual patient and departmental management.

#### Ocular

- Describe the indications, limitations, and relative contraindications of ocular CUS.
- Perform CUS protocols for the detection of
  - Vitreous hemorrhage
  - Posterior vitreous detachment
  - Retinal detachment
  - Optic nerve sheath diameter measurement
  - Optic disc evaluation
- Advanced evaluation
  - Lens pathology
  - Foreign body
  - Globe rupture
  - Retrobulbar hematoma
  - Central retinal artery/vein occlusion
  - Subretinal hemorrhage
- Light reflex
  - Identify relevant US anatomy of the globe and orbital structures.
  - Recognize the relevant findings and pitfalls when evaluating for ocular pathology.
- Integrate ocular CUS into individual patient and departmental management.

#### Procedural Guidance

- Describe the indications and limitations when using US guidance for bedside procedures.
- Perform CUS protocols for procedural guidance including both transverse and longitudinal approaches when appropriate. These procedures may include:
  - Vascular access: Central and peripheral
  - Confirmation of endotracheal intubation
  - Pericardiocentesis
  - Paracentesis
  - Thoracentesis
  - Foreign body detection and removal
  - Evaluation and aspiration/drainage of body fluid
  - Arthrocentesis
  - Pacemaker placement and capture
  - Abscess identification and drainage
  - Regional anesthesia
- Identify relevant US anatomy for each particular procedure.
- Recognize the relevant findings and pitfalls when performing CUS for procedural guidance.
- Integrate CUS for procedural guidance into individual patient and departmental management.

#### Bowel

- Describe the indications and limitations of bowel CUS
- Perform CUS protocols for the detection of:
  - Acute appendicitis
  - Small and Large Bowel obstruction
  - Pneumoperitoneum
  - Diverticulitis
  - Hernia
  - Intussusception and Pyloric Stenosis
  - Evaluation/placement of orogastric/nasogastric or percutaneous gastronomy tube
- Identify relevant US anatomy of bowel structures.
- Recognize the relevant findings and pitfalls when evaluating for bowel pathology
- Integrate bowel CUS findings into individual patient and departmental management.

#### Transesophageal Echocardiography (TEE)

- Describe the indications, limitations, and contraindications to resuscitative TEE.
- Perform standard TEE views to evaluate for cardiac pathology, guidance of chest compressions in cardiopulmonary resuscitation, and procedures, such as pericardiocentesis, pacemaker placement, and ECMO catheter placement.
- Advanced evaluation:
  - Regional wall motion abnormalities
  - Aortic dissection
  - Aortic aneurysm

#### **Appendix 4. Recommendations for an EM Residency CUS Education Program**

Successful EUS Residency Education in accordance with these guidelines requires significant departmental and institutional support. The purpose of these additional recommendations is to delineate the scope of resources required to facilitate the development and maintenance of CUS Residency Education programs. Application of these recommendations is dependent on EM residency size, current and planned CUS utilization, and institutional capabilities.

##### CUS Faculty:

1. CUS Director: At least one full time EM attending faculty with sufficient CUS program coordination expertise. Sufficient non-clinical time for planning and conducting all CUS program activities is essential to ensuring adequate resident training.
2. CUS Faculty: At least one additional full time EM attending faculty member committed to actively developing CUS expertise. Sufficient non-clinical time for conducting CUS program activities is essential to ensuring adequate resident training. The number of dedicated CUS faculty needed is dependent on the size of the residency and quality of the training program desired.
3. Credentialed CUS Faculty: To adequately supervise and educate residents in CUS, a minimum of fifty percent of Core Faculty members at all EM residency programs need to be credentialed in CUS. For example, if a program has 12 core faculty, then 6 need to be credentialed in CUS. May be inclusive of the CUS Director and Faculty.

##### Equipment and Materials:

1. CUS systems with appropriate transducers and imaging capabilities readily available for immediate resident clinical use 24/7.
2. CUS educational (online and/or print) resources readily available for access.
3. Recent and landmark CUS literature as well as opportunities to participate in local quality improvement and research projects need to be provided to residents and core US faculty.

##### Curriculum Components and Competency Assessment:

1. Initial CUS Training: Didactic and hands-on instruction in CUS physics, machine use, and introduction to core CUS applications need to be provided early in residency as a half or full day course.
2. Annual CUS Rotations: Two-week rotation in the first year to learn basic EUS knowledge and skills, followed by at least one week in each subsequent year to reinforce learning and acquire more advanced skills. One rotation without continued learning within the EM residency curriculum is inadequate. For each trainee, a minimum of 80 hours of dedicated EUS rotation time is recommended during an EM residency.
3. Suggested rotation educational methods and assessment measures:
  - a. Orientation: Begin rotation with a baseline CUS skills assessment to identify trainee's unique learning needs. Follow with hands-on small group instruction in the ED focusing on machine operation, exam protocols, image optimization and interpretation, documentation, as well as integration of CUS findings into daily clinical practice.
  - b. Scheduled supervised scanning shifts with CUS faculty in the ED to provide opportunities for both proctored and semi-independent image acquisition and interpretation. All training exams are submitted for timely quality assurance review.
  - c. Weekly Academic Day:
    - i. Quality Assurance/Improvement Review session during which a portion of current trainee's CUS exams are discussed, focusing on challenging cases, pathology, and integration into daily patient and ED management.
    - ii. Simulation cases and review of image libraries for additional exposure to less common pathology.



- iii. Journal club including a discussion of a recent or landmark CUS literature, an online narrated didactic or live lecture, or chapter review.
- iv. Hands-on small group instruction in the ED focusing on current trainees learning needs identified during QA/QI Review or scanning shifts.
- d. End the rotation with a final assessment of CUS knowledge utilizing a standardized exam such as the ACEP US Online Exams, as well as an additional CUS skill assessment.
- e. Provide a timely end of CUS rotation assessment of knowledge and skills to each resident. Additionally, provide trainees with continued opportunities to evaluate the CUS program itself.
- 4. Achieving CUS exam requirements: Completion of set number examinations documents adequate experience to develop proficiency. Additional assessment measures described in these guidelines are needed to ensure CUS competency such as participation in QA/QI sessions, SDOTs, OSCEs, and simulation assessments. CUS directors can certify CUS training at the end of residency.
- 5. Ongoing Quality Assurance System: Digital archiving system for CUS exam images and interpretations for timely quality assurance review and trainee feedback on individual exams which includes technique and image interpretation.
  - a. All trainee exams need to be reviewed by CUS faculty until minimum benchmarks are achieved. After this, a proportion of trainee exams need to be reviewed on an ongoing basis throughout residency.
  - b. Timely exam feedback must be provided to trainees during and between CUS rotations. Trainees need ready access to individual exam feedback and total exams completed by application and overall.
- 6. Integrated CUS training in the residency curriculum: Learning needs to be reinforced during quarterly or biannual EUS workshops comprised of CUS didactics and hands-on instruction. An additional 20 hours of dedicated CUS learning between rotations is recommended during a 3 or 4 year residency.

## Appendix 5. Recommendations for a CUS Course

Successful training courses in CUS require significant advance planning and resource commitment. The curriculum designed by the course director should include a trainee needs assessment, educational learning objectives, educational methods, and assessment measures. The learning objectives for any CUS Course or rotation are listed in Appendix 3. Important considerations are discussed below

1. **Faculty:** The course director must be a physician and known expert in clinical ultrasound. The course director should recruit other clinicians already credentialed in CUS to assist with knowledge learning, skills training, and trainee assessment. Several faculty planning meetings are recommended during curriculum development as well as a meeting immediately prior to the course to provide all faculty with an understanding of the setup, curriculum, and logistics.
2. **Site and Set Up:** The ideal course site includes a large didactic room as well as separate rooms or areas for scanning stations. Private areas for endovaginal US are required if this topic will be covered during training.
  - a. **Ultrasound Stations:** Appropriate machines and transducers are necessary. The learner to instructor ratio should be no higher than 5 to 1 to ensure appropriate skills training.
  - b. **Ultrasound Models:** Image acquisition protocols may be learned on normal live models. Image interpretation requires the incorporation of patients with known pathologic findings, simulators, or incorporation of image libraries.
    - i. Pathology models may include otherwise healthy paid or volunteer persons with pericardial effusions, cholelithiasis, aortic aneurysms and chronic ambulatory peritoneal dialysis patients.
    - ii. Full informed consent should be obtained from all models and a signed waiver of responsibility is recommended. If an undiagnosed finding is discovered in a model, then the course director must appropriately notify the model and ensure appropriate follow up.
3. **Knowledge Learning:**
  - a. An introductory course for trainees must include instruction in basic US physics, machine operation, and a small number of initial CUS applications to be clinically utilized. Suggested initial applications include Trauma Ultrasound, Central and Peripheral Venous Access, and Abdominal Aortic Aneurysm ultrasound. However, the initial applications will vary by local site as determined by a pre-course needs assessment completed by the course director and local trainee leadership.
    - i. A half-day introductory course is appropriate for a single application. Longer courses are required for additional applications. Shorter, repeated courses, supplemented by routine, quality assured, CUS performance during clinical work, are more likely to improve learning and utilization.
  - b. Pre- and post-course educational materials must be provided to reinforce course learning. Suggested sources of information include course director approved online narrated lectures, podcasts, websites, traditional textbooks, didactic syllabi, and journal articles.
    - i. Utilization of the flipped classroom provides the opportunity for more focused didactics reviewing key concepts and answering trainee questions at the course. Focused didactics provide the opportunity for increased skill training.
    - ii. Frequent rotations between didactics and skills training sessions improve trainee and faculty engagement.
4. **Skills Training:**  
The technical laboratory is an integral component of any ultrasound course.

- a. Based on the needs assessment, appropriate and specific learning objectives need to be defined for each station.
  - i. Trainees should be deliberately assigned to small groups not necessarily including immediate peers to create more focused learning teams.
  - ii. For trainees with prior CUS experience, an initial skills assessment with an SDOT or simulator will help to ensure that trainee specific instruction is provided.
  - iii. Instructors should work to maximize the time that the transducer is the trainee's' hands, avoid over teaching of advanced concepts beyond the trainees needs, encourage questions, and consistently engage each trainee.

## Appendix 6. CUS Training for Medical Students

CUS Training during a one-month EM Rotation:

General EM clerkships should include an introduction to CUS that may entail a single dedicated clinical US shift with direct faculty supervision, a one-day CUS course, or simply case-by-case incorporation of CUS into patient care in the ED. Students should strive to become familiar with a single CUS application such as the FAST exam, and should be exposed to additional CUS exams over the course of the clerkship. CUS literature, selected textbook chapters, online modules or digital resources should be made available for student review.

Dedicated CUS rotation recommendations:

1. Emergency US and CUS rotations should begin with instruction in Physics/Instrumentation, followed by select applications such as FAST, Aorta, Renal, Hepatobiliary Cardiac, Procedures, Pelvic (including endovaginal US), Deep Venous Thrombosis, Skin and Soft Tissue, and Musculoskeletal.
2. Didactic education should be delivered in electronic, preferably online, format in an attempt to maximize hands-on education in the clinical area. A reliable resource that course directors may choose to utilize for US didactic material is the ACEP Sonoguide website. available on the ACEP Web site ([www.acep.org/sonoguide](http://www.acep.org/sonoguide)).
3. Assessments should include a pre-test including still image/video interpretation and case-based applications of CUS. To assess their progress, the same test may be completed at the end of the rotation.
4. Each student should obtain between 75 to 100 scans over the course of a 4-week rotation, or approximately 40-50 scans over the course of a 2-week rotation. Dedicated shifts may include evenings or weekends to maximize exposure to pathology and interesting emergency US cases. If digital tracking is not available, students should generate a personal log of CUS exams on which to build during their postgraduate education.
5. All student-performed scans should be directly supervised by CUS credentialed faculty or recorded for subsequent quality assurance review with the rotation director or adjunct ultrasound faculty.
6. Students should complete the reading of an assigned CUS text or viewing of an assigned online curriculum over the course of the rotation. In addition, it is recommended that students identify a current publication relevant to CUS to discuss their findings with the rotation director.

Additional Opportunities for CUS Training in Undergraduate Medical Education:

With the advent of more US in various specialties, this preparation in medical school can benefit students with interests outside of emergency medicine.

Emergency and Clinical US directors could consider incorporating US into:

1. Gross anatomy course highlighting common US anatomy (eg, FAST exam during study of the abdomen, heart)
2. Physiology course highlighting doppler, M mode, and basic waveform analysis.
3. Pathology course highlighting common pathologies such as fluid in potential spaces, depressed cardiac function, cellulitis, abscess, retinal detachment or other commonly seen pathologies in the ED.
4. Introduction to Clinical Medicine course highlighting US guided vascular access.
5. Ultrasound in the physical exam. Although US use in clinical practice is a diagnostic test that warrants a generated report, it can be used to teach components of the physical exam. For example, teaching the traditional cardiac auscultation can be augmented with cardiac images of the heart.
6. Ultrasound training before clinical rotations. Some schools have developed short clinical skills time before rotations where US can be implemented to help student learners see how US is used in that particular field.
7. Ultrasound electives in the 4th year can include a longitudinal program where US lectures, hands on, and journal club can be incorporated into a course.

The future of US in medical education is constantly being built, modified and ever evolving. Though it seems like there are early adopters trying to implement CUS in medical education. one of the key components is finding an US champion to spearhead CUS into the undergraduate medical education framework. From there, getting students involved through an US interest group can improve the impact through direct feedback and student motivation. The two methods of a top-down administrative implementation of US in medical education are the best method, yet warrants buy in from the dean and the curriculum committee. A bottom up approach through student interest, electives and extracurricular exposure takes longer but can still impact student competence in US.

**ACEP Emergency Ultrasound Section Writing Committee and Contributors:**

Editors: Arun Nagdev MD; Penelope C. Lema, MD, FACEP; Javier E. Rosario MD, FACEP; Elaine Situ-LaCasse, MD; and Michael Gottlieb, MD, FACEP

Introduction: Arun Nagdev MD; Penelope C. Lema, MD, FACEP; Michael Gottlieb, MD, FACEP

Scope of Practice: Vivek S. Tayal, MD, FACEP; Christopher C. Raio, MD, FACEP

Training: John M. Bailitz, MD, FACEP; Stephen J. Leech, MD, FACEP; Romolo J. Gaspari, MD, PhD, FACEP

Credentialing: Robert A. Jones, DO, FACEP; Thompson Kehrl, MD, FACEP; Romolo J. Gaspari MD, PhD, FACEP

Quality Assurance: J. Matthew Fields, MD, FACEP

Value and Reimbursement: Romolo J. Gaspari, MD, PhD, FACEP and Michael Gottlieb, MD, FACEP

Institutional Leadership: Resa Lewiss MD; Gerardo C. Chiricolo, MD, FACEP

Future issues: Srikar R. Adhikari MD, MS, FACEP

Core and Advanced Applications: Lindsay A. Taylor MD, FACEP; Megan Leo, MD; Judy C. Lin MD, FACEP; Sara Damewood, MD, FACEP; Frances Russell, MD, FACEP; Dan Mantuani MD; Di Coneybeare, MD, MHPE; Amy Marks MD; Josie G. Acuña MD; Stephen Alerhand, MD; Petra Duran-Gehring, MD, FACEP; Margaret Lin-Martore, MD; Lori A. Stolz, MD, FACEP; Rachel B. Liu MD, FACEP; Felipe Teran, MD, FACEP; Laura Oh MD, FACEP; Michael Gottlieb MD, FACEP.

**References**

1. Chiu L, Jairam MP, Chow R, et al. Meta-analysis of point-of-care lung ultrasonography versus chest radiography in adults with symptoms of acute decompensated heart failure. *Am J Cardiol.* 2022;174:89-95.
2. Fields JM, Davis J, Alsup C, et al. Accuracy of point-of-care ultrasonography for diagnosing acute appendicitis: A systematic review and meta-analysis. *Acad Emerg Med.* 2017;24(9):1124-36.
3. Gottlieb M, Patel D, Marks A, Peksa GD. Ultrasound for the diagnosis of shoulder dislocation and reduction: A systematic review and meta-analysis. *Acad Emerg Med.* 2022;29(8):999-1007.
4. Tran QK, Fairchild M, Yardi I, Mirda D, Markin K, Pourmand A. Efficacy of ultrasound-guided peripheral intravenous cannulation versus standard of care: A systematic review and meta-analysis. *Ultrasound Med Biol.* 2021;47(11):3068-78.
5. Gu WJ, Wu XD, Wang F, Ma ZL, Gu XP. Ultrasound guidance facilitates radial artery catheterization: A meta-analysis with trial sequential analysis of randomized controlled trials. *Chest.* 2016;149(1):166-79.
6. Gottlieb M, Holladay D, Peksa GD. Ultrasound-assisted lumbar punctures: A systematic review and meta-Analysis. *Acad Emerg Med.* 2019;26(1):85-96.

7. Heller MB, Mandavia D, Tayal VS, et al. Residency training in emergency ultrasound: fulfilling the mandate. *Acad Emerg Med.* 2002;9:835-9.
8. ACR-SPR-SRU Practice Parameter for Performing and Interpreting Diagnostic Ultrasound Examinations. 2017. Accessed December 2022 at <https://www.acr.org/-/media/ACR/Files/Practice-Parameters/us-perf-interpret.pdf>
9. ACEP Emergency Ultrasound Section. Emergency Ultrasound Coding and Reimbursement Document. 2021. Accessed December 2022 at <https://www.acep.org/emultrasound/subcommittees/coding-reimbursement/>
10. Geria RN, Raio CC, Tayal V. Point-of-care ultrasound: not a stethoscope-a separate clinical entity. *J Ultrasound Med.* 2015;34:172-3.
11. American College of Emergency Physicians. Definition of Clinical Ultrasonography [policy statement]. Reaffirmed June 2022. Accessed December 2022 at <https://www.acep.org/patient-care/policy-statements/definition-of-clinical-ultrasonography>
12. American College of Emergency Physicians. Emergency Ultrasound Imaging Criteria Compendium [policy statement]. Approved October 2021. Accessed December 2022 at <https://www.acep.org/patient-care/policy-statements/Emergency-Ultrasound-Imaging-Criteria-Compendium/>
13. Shah VP, Tunik MG, Tsung JW. Prospective evaluation of point-of-care ultrasonography for the diagnosis of pneumonia in children and young adults. *JAMA Pediatr.* 2013;167:119-25.
14. Gallagher RA, Levy J, Vieira RL, et al. Ultrasound assistance for central venous catheter placement in a pediatric emergency department improves placement success rates. *Acad Emerg Med.* 2014;21:981-6.
15. Elikashvili I, Tay ET, Tsung JW. The effect of point-of-care ultrasonography on emergency department length of stay and computed tomography utilization in children with suspected appendicitis. *Acad Emerg Med.* 2014;21:163-70.
16. Bartocci M, Fabrizi G, Valente I, et al. Intussusception in childhood: role of sonography on diagnosis and treatment. *J Ultrasound.* 2015;18:205-11.
17. Plumb J, Mallin M, Bolte RG. The role of ultrasound in the emergency department evaluation of the acutely painful pediatric hip. *Pediatr Emerg Care.* 2015;31:54-8; quiz 9-61.
18. Deanehan J, Gallagher R, Vieira R, et al. Bedside hip ultrasonography in the pediatric emergency department: a tool to guide management in patients presenting with limp. *Pediatr Emerg Care.* 2014;30:285-7.
19. Marin JR, Lewiss RE, AAP, et al. Point-of-care ultrasonography by pediatric emergency medicine physicians. *Pediatrics.* 2015;135(4):e1113-22.
20. Vieira RL, Hsu D, Nagler J, et al. Pediatric emergency medicine fellow training in ultrasound: consensus educational guidelines. *Acad Emerg Med.* 2013;20:300-6.
21. Zieleskiewicz L, Muller L, Lakhali K, et al. Point-of-care ultrasound in intensive care units: assessment of 1073 procedures in a multicentric, prospective, observational study. *Intensive Care Med.* 2015;41:1638-47.
22. Gallard E, Redonnet JP, Bourcier JE, et al. Diagnostic performance of cardiopulmonary ultrasound performed by the emergency physician in the management of acute dyspnea. *Am J Emerg Med.* 2015;33:352-8.
23. Nelson BP, Sanghvi A. Out of hospital point of care ultrasound: current use models and future directions. *Eur J Trauma Emerg Surg.* 2016;42:139-50.
24. Press GM, Miller SK, Hassan IA, et al. Evaluation of a training curriculum for prehospital trauma ultrasound. *J Emerg Med.* 2013;45:856-64.

25. Taylor J, McLaughlin K, McRae A, et al. Use of prehospital ultrasound in North America: a survey of emergency medical services medical directors. *BMC Emerg Med.* 2014;14:6.
26. Shorter M, Macias DJ. Portable handheld ultrasound in austere environments: use in the Haiti disaster. *Prehosp Disaster Med.* 2012;27:172-7.
27. Zhou J, Huang J, Wu H, et al. Screening ultrasonography of 2,204 patients with blunt abdominal trauma in the Wenchuan earthquake. *J Trauma Acute Care Surg.* 2012;73:890-4.
28. Zhang S, Zhu D, Wan Z, et al. Utility of point-of-care ultrasound in acute management triage of earthquake injury. *Am J Emerg Med.* 2014;32:92-5.
29. Raja AS, Propper BW, Vandenberg SL, et al. Imaging utilization during explosive multiple casualty incidents. *J Trauma.* 2010;68:1421-4.
30. Shah S, Dalal A, Smith RM, et al. Impact of portable ultrasound in trauma care after the Haitian earthquake of 2010. *Am J Emerg Med.* 2010;28:970-1.
31. Kirkpatrick AW, Campbell MR, Novinkov OL, et al. Blunt trauma and operative care in microgravity: a review of microgravity physiology and surgical investigations with implications for critical care and operative treatment in space. *J Am Coll Surg.* 1997;184:441-53.
32. Campbell MR, Billica RD, Johnston SL, et al. Performance of advanced trauma life support procedures in microgravity. *Aviat Space Environ Med.* 2002;73:907-12.
33. Russell TC, Crawford PF. Ultrasound in the austere environment: a review of the history, indications, and specifications. *Mil Med.* 2013;178:21-8.
34. Rozanski TA, Edmondson JM, Jones SB. Ultrasonography in a forward-deployed military hospital. *Mil Med.* 2005;170:99-102.
35. Morgan AR, Vasios WN, Hubler DA, et al. Special operator level clinical ultrasound: an experience in application and training. *J Spec Oper Med.* 2010;10:16-21.
36. Strode CA, Rubal BJ, Gerhardt RT, et al. Satellite and mobile wireless transmission of focused assessment with sonography in trauma. *Acad Emerg Med.* 2003;10:1411-4.
37. Bahner DP, Goldman E, Way D, Royall NA, Liu YT. The state of ultrasound education in U.S. medical schools: results of a national survey. *Acad Med.* 2014;89:1681-6.
38. Soni NJ, Schnobrich D, Matthews BK, Tierny DM, Jensen TP, Dancel R, et al. Point-of-Care Ultrasound for Hospitalists: A Position Statement of the Society of Hospital Medicine. *J Hosp Med.* 2019;14:E1-E6.
39. Beal EW, Sigmond BR, Sage-Silski L, Lahey S, Nguyen V, Bahner DP. Point-of-care ultrasound in general surgery residency training: A proposal for milestones in graduate medical education ultrasound. *J Ultrasound Med.* 2017;36:2577-84.
40. Young AC, Butts C, deBoisblanc BP, Tejedor RS, Kantrow SP, Lammi MR. Implementation of a longitudinal critical care fellowship ultrasound curriculum. *ATS Scholar.* 2022;3:125-34.
41. Smalley CM, Fertel BS, Broderick E. Standardizing point-of-care ultrasound credentialing across a large health care system. *Jt Comm J Qual Patient Saf.* 2020;46:471-6.
42. Bahner DP, Hughes D, Royall NA. I-AIM: a novel model for teaching and performing focused sonography. *J Ultrasound Med.* 2012;31:295-300.
43. Damewood SC, Leo M, Bailitz J, Gottlieb M, Liu R, Hoffmann B, et al. Tools for measuring clinical ultrasound competency: recommendations from the Ultrasound Competency Work Group. *AEM Educ Train.* 2020;4:S106-S112.
44. Panebianco NL, Liu RB, Alerhand S, Au AK, Bailitz J, Chiem AT, et al. Joint recommendations and resources for clinical ultrasound education amidst the COVID-19 era. *AEM Educ Train.* 2020;4:438-42.
45. Smalley CM, Browne V, Kaplan B, Russ B, Wilson J, Lewiss RE. Early innovative immersion: a course for pre-medical professions students using point-of-care ultrasound. *J Ultrasound Med.* 2016;35:2681-6.



46. Smalley CM, Sande M, Wilson J, Lewiss RE. An education innovation to improve point-of-care ultrasound skills in senior emergency medicine residents: a mandatory advanced rotation. *J Medic Educ Training*. 2017;1:001.
47. American College of Emergency Physicians. Sonoguide. Accessed December 2022: <https://www.acep.org/sonoguide/>
48. Society for Academic Emergency Medicine Academy for Emergency Ultrasound Asynchronous Ultrasound Curriculum. In: Default [Internet]. Accessed December 2022. Available: <https://www.saem.org/about-saem/academies-interest-groups-affiliates2/aeus/education/aeus-off-the-shelf-asynchronous-ultrasound-curriculum>
49. Miller GT, Scerbo MW, Zybak S, Byars DV, Goodmurphy CW, Lattanzio FA, et al. Learner improvement from a simulation-enhanced ultrasonography curriculum for first-year medical students. *J Ultrasound Med*. 2017;36:609-19.
50. Damewood SC, Lewiss RE, Huang JV. Ultrasound simulation utilization among point of care ultrasound users: Results of a survey. *J Clin Ultrasound*. 2018;46:571-4.
51. Smith S, Lobo V, Anderson KL, Gisondi MA, Sebok-Syer SS, Duanmu Y. A randomized control trial of simulation-based mastery learning to teach the extended focused assessment with sonography in trauma. *AEM Educ Train*. 2021. doi:10.1002/aet2.10606
52. Harel-Sterling M, McLean LJ. Development of a blended learning curriculum to improve POCUS education in a pediatric emergency medicine training program. *CJEM*. 2022;24:325-8.
53. Stolz LA, Amini R, Situ-LaCasse E, Acuña J, Irving SC, Friedman L, et al. Multimodular ultrasound orientation: residents' confidence and skill in performing point-of-care ultrasound. *Cureus*. 2018;10:e3597.
54. Lewiss RE, Hayden GE, Murray A, Liu YT, Panebianco N, Liteplo AS. SonoGames: an innovative approach to emergency medicine resident ultrasound education. *J Ultrasound Med*. 2014;33:1843-9.
55. Liteplo AS, Carmody K, Fields MJ, Liu RB, Lewiss RE. SonoGames: Effect of an innovative competitive game on the education, perception, and use of point-of-care ultrasound. *J Ultrasound Med*. 2018;37:2491-6.
56. PoSaw LL, Wubben BM, Bertucci N, Bell GA, Healy H, Lee S. Teaching emergency ultrasound to emergency medicine residents: a scoping review of structured training methods. *J Am Coll Emerg Physicians Open*. 2021;2:e12439.
57. Duanmu Y, Henwood PC, Takhar SS, Chan W, Rempell JS, Liteplo AS, et al. Correlation of OSCE performance and point-of-care ultrasound scan numbers among a cohort of emergency medicine residents. *Ultrasound J*. 2019;11(1):3.
58. Anders Ericsson K. Deliberate practice and acquisition of expert performance: A general overview. *Acad Emerg Med*. 2008;15:988-94.
59. Saxena M, Tan TX, Duanmu Y, Ashenburg N, Ghaziaskar Z. Seeing (virtually) is believing: The utility of teleultrasound education for the focused assessment with sonography for trauma exam. *Acad Emerg Med*. 2021;S403-S403.
60. Young K, Moon N, Wilkinson T. Building point-of-care ultrasound capacity in rural emergency departments: An educational innovation. *Can J Rural Med*. 2021;26:169-175.
61. Narang A, Bae R, Hong H, Thomas Y, Surette S, Cadieu C, et al. Utility of a deep-learning algorithm to guide novices to acquire echocardiograms for limited diagnostic use. *JAMA Cardiol*. 2021;6:624-32.
62. Adhikari S, Amini R, Stolz L, O'Brien K, Gross A, Jones T, et al. Implementation of a novel point-of-care ultrasound billing and reimbursement program: fiscal impact. *Am J Emerg Med*. 2014;32:592-5.
63. Beeson MS, Carter WA, Christopher TA, Heidt JW, Jones JH, Meyer LE, et al. The development of the emergency medicine milestones. *Acad Emerg Med*. 2013;20:724-9.
64. Lewiss RE, Pearl M, Nomura JT, Baty G, Bengiamin R, Duprey K, et al. CORD-AEUS: consensus document for the emergency ultrasound milestone project. *Acad Emerg Med*. 2013;20:740-5.

65. Cooney RR, Murano T, Ring H, Starr R, Beeson MS, Edgar L. The Emergency Medicine Milestones 2.0: Setting the stage for 2025 and beyond. *AEM Educ Train*. 2021;5:e10640.
66. Russell FM, Kennedy SK, Rood LK, Nti B, Herbert A, Rutz MA, et al. Design and implementation of a basic and global point of care ultrasound (POCUS) certification curriculum for emergency medicine faculty. *Ultrasound J*. 2022;14:10.
67. Budhram G, Elia T, Rathlev N. Implementation of a successful incentive-based ultrasound credentialing program for emergency physicians. *West J Emerg Med*. 2013;14:602-8.
68. American College of Emergency Physicians. Guidelines Regarding the Role of Physician Assistants and Nurse Practitioners in the Emergency Department [policy statement]. Approved March 2022.
69. Strony R, Marin JR, Bailitz J, Dean AJ, Blaivas M, Tayal V, et al. Systemwide clinical ultrasound program development: An expert consensus model. *West J Emerg Med*. 2018;19:649-53.
70. Accrediting Advanced Emergency Ultrasound Fellowships. In: Emergency Ultrasound Fellowship Accreditation Council – [Internet]. [cited 29 Apr 2022]. Available: <https://eufacouncil.org/>
71. Advanced EM Ultrasonography. In: American Board of Emergency Medicine [Internet]. [cited 29 Apr 2022]. Available: <https://www.abem.org/public/become-certified/focused-practice-designation/advanced-em-ultrasonography>
72. Gottlieb M, Duran-Gehring P, Coneybeare D, Lema P. Creation of a novel course for the advanced emergency medicine ultrasound focused practice designation examination. *AEM Educ Train*. 2022;6(5):e10810.
73. Davis JJ, Wessner CE, Potts J, Au AK, Pohl CA, Fields JM. Ultrasonography in Undergraduate Medical Education: A Systematic Review. *J Ultrasound Med*. 2018;37:2667-79.
74. American Medical Association. H-230.960 Privileging for Ultrasound Imaging. Accessed December, 7, 2022, at <https://policysearch.ama-assn.org/policyfinder/detail/privileging%20for%20ultrasound%20imaging?uri=%2FAMADoc%2FHOD.xml-0-1591.xml>
75. American College of Emergency Physicians. Emergency Ultrasound Certification by External Entities [policy statement]. Reaffirmed February 2020. Accessed December 2022 at <https://www.acep.org/patient-care/policy-statements/emergency-ultrasound-certification-by-external-entities>
76. OPPE and FPPE: Tools to help make privileging decisions. The Joint Commission, 2020. Accessed December 2022, at <https://www.jointcommission.org/standards/standard-faqs/hospital-and-hospital-clinics/medical-staff-ms/000002291/>
77. American College of Emergency Physicians. ACEP Emergency Ultrasound Standard Reporting Guidelines [Internet]. 2018 [cited 2022 Apr 28]. Available from: <https://www.acep.org/globalassets/uploads/uploaded-files/acep/clinical-and-practice-management/policy-statements/information-papers/emergency-ultrasound-standard-reporting-guidelines---2018.pdf>
78. Byrne M, Geria R, Kummer T, Leech S, Lewiss R, Noble V, et al. Emergency ultrasound: workflow white paper. ACEP [accessed 24 July 2018] [Internet]. Available from: <https://www.acep.org/globalassets/uploads/uploaded-files/acep/membership/sections-of-membership/ultra/workflow-white-paper.pdf>
79. ACEP. Ultrasound Services in the Emergency Department. [policy statement]. Approved June 2022. Available from: <https://www.acep.org/patient-care/policy-statements/ultrasound-services-in-the-emergency-department/>
80. Byrne M, ACEP Emergency Ultrasound Section. Essential Machine Features [Internet]. 2014 [cited 2022 Apr 28]. Available from: <https://www.acep.org/globalassets/uploads/uploaded-files/acep/membership/sections-of-membership/ultra/essential-machine-features-2014.pdf>
81. American College of Emergency Physicians. Appropriate Use Criteria for Handheld/Pocket Ultrasound Devices [Internet]. 2018 [cited 2022 Apr 28]. Available from: <https://www.acep.org/globalassets/new-pdfs/policy-statements/appropriate-use-criteria-for-handheld->

- [pocket-ultrasound-devices.pdf](#)
82. Stolz L, O'Brien KM, Miller ML, Winters-Brown ND, Blaivas M, Adhikari S. A review of lawsuits related to point-of-care emergency ultrasound applications. *West J Emerg Med.* 2015;16(1):1-4.
  83. Labovitz AJ, Noble VE, Bierig M, et al. Focused cardiac ultrasound in the emergent setting: a consensus statement of the American Society of Echocardiography and American College of Emergency Physicians. *J Am Soc Echocardiogr.* 2010;23:1225-30.
  84. Gaspari R, Dickman E. Effect of performing but not billing for emergency ultrasound in the emergency department. *Ann Emerg Med.* 2005. 46(3s).S21.
  85. Sierzenski PR, Fletcher S, O'Connor RE. 276: Emergency physicians who use ultrasound demonstrate higher performance parameters compared to colleagues who are rare users, independent of the clinical hours or shift type worked. *Ann Emerg Med.* 2007;50(3): Supplement S87.
  86. Dean AJ, Zwank M, Strony R, Marin J. System Wide Clinical Ultrasound Resources. ACEP. <https://www.acep.org/emultrasound/subcommittees/system-wide-ultrasound-directors/>
  87. Philips Lumify. Accessed May 5, 2022, at <https://www.usa.philips.com/healthcare/sites/lumify>
  88. EchoNous. Accessed May 5, 2022, at [https://echonous.com/en\\_us/](https://echonous.com/en_us/)
  89. GE Vscan Air. Accessed May 5, 2022, at <https://www.gehealthcare.com/products/ultrasound/handheld-ultrasound-vscan>
  90. Butterfly iQ+. Accessed May 5, 2022, at <https://www.butterflynetwork.com/>
  91. EXO works. Accessed May 5, 2022, at <https://www.exo.inc/>
  92. Hsieh A, Baker MB, Phalen JM, et al. Handheld point-of-care ultrasound: safety considerations for creating guidelines. *J Intensive Care Med.* 2022;37(9):1146-51.
  93. McGahan J, Pozniak, M, Cronan J, Pellerito J, Lee K, Blaivas, M. Handheld ultrasound: Threat or opportunity? *Appl Radiol.* March 09, 2015.
  94. ECRI. Top 10 health technology hazards for 2020: ECRI Institute. Accessed May 5, 2022, at <https://www.ecri.org/landing-2020-top-ten-health-technology-hazards>
  95. Marsh-Feiley G, Eadie L, Wilson P. Telesonography in emergency medicine: A systematic review. *PLoS One.* 2018;13(5):e0194840.
  96. Clinical Ultrasound Accreditation Program. <http://www.cuap.org>
  97. Rubano, E, Mehta N, Caputo W, Paladino L, Sinert R. Systematic review: emergency department bedside ultrasonography for diagnosing suspected abdominal aortic aneurysm *Acad Emerg Med.* 2013;20:128-38.
  98. Mai T, Woo M, Boles K, Jetty P. Point of care ultrasound performed by a medical student compared to physical examination by vascular surgeons in the detection of abdominal aortic aneurysms. *Ann Vasc Surg.* 2018;52:15-21.
  99. Guirguis-Blake JM, Beil TL, Senger CA, Coppola EL. Primary care screening for abdominal aortic aneurysm: a systematic evidence review for the U.S. Preventive Services Task Force. Agency for Healthcare Research and Quality (US), Rockville (MD); 2019.
  100. Hoffmann B, Um P, Bessman ES, Ding R, Kelen GD, McCarthy ML. Routine screening for asymptomatic abdominal aortic aneurysm in high-risk patients is not recommended in emergency departments that are frequently crowded. *Acad Emerg Med.* 2009;16:1242-50.
  101. Wang Y, Yu H, Cao Y, Wan Z. Early screening for aortic dissection with point-of-care ultrasound by emergency physicians. *J Ultrasound Med.* 2020;39:1309-15.
  102. Catalano O, Siani A. Ruptured abdominal aortic aneurysm. *J Ultrasound Med.* 2005;24:1077-83.
  103. Nazerian P, Mueller C, Vanni S, et al. Integration of transthoracic focused cardiac ultrasound in the diagnostic algorithm for suspected acute aortic syndromes. *Eur Heart J.* 2019;40(24):1952-60.
  104. Sobczyk D, Nycz K. Feasibility and accuracy of bedside transthoracic echocardiography in diagnosis of acute proximal aortic dissection. *Cardiovasc Ultrasound.* 2015;13:15.
  105. Erbel R, Aboyans V, Boileau C, et al. 2014 ESC Guidelines on the diagnosis and treatment of aortic diseases: Document covering acute and chronic aortic diseases of the thoracic and abdominal aorta of the adult. The Task Force for the Diagnosis and Treatment of Aortic Diseases of the European

- Society of Cardiology (ESC) [published correction appears in *Eur Heart J*. 2015;1;36(41):2779.
106. Howell JM, Eddy OL, Lukens TW, et al. Clinical policy: Critical issues in the evaluation and management of emergency department patients with suspected appendicitis. *Ann Emerg Med*. 2010;55(1):71-116.
  107. Elikashvili I, Tay ET, Tsung JW. The effect of point-of-care ultrasonography on emergency department length of stay and computed tomography utilization in children with suspected appendicitis. *Acad Emerg Med*. 2014;21(2):163-70.
  108. Gottlieb M, Peksa GD, Pandurangadu AV, Nakitende D, Takhar S, Seethala RR. Utilization of ultrasound for the evaluation of small bowel obstruction: A systematic review and meta-analysis. *Am J Emerg Med*. 2018;36(2):234-42.
  109. Boniface KS, King JB, LeSaux MA, Haciski SC, Shokoohi H. Diagnostic accuracy and time-saving effects of point-of-care ultrasonography in patients with small bowel obstruction: A prospective study. *Ann Emerg Med*. 2020;75(2):246-56.
  110. Laméris W, van Randen A, Bipat S, Bossuyt PM, Boormeester MA, Stoker J. Graded compression ultrasonography and computed tomography in acute colonic diverticulitis: meta-analysis of test accuracy. *Eur Radiol*. 2008;18(11):2498-511.
  111. Cohen A, Li T, Stankard B, Nelson M. A prospective evaluation of point-of-care ultrasonographic diagnosis of diverticulitis in the emergency department. *Ann Emerg Med*. 2020 Dec;76(6):757-766.
  112. Nazerian P, Gigli C, Donnarumma E, et al. Diagnostic accuracy of point-of-care ultrasound integrated into clinical examination for acute diverticulitis: A prospective multicenter study. *Ultraschall Med*. 2021;42(6):614-22.
  113. Yum J, Hoffman T, Naraghi L. Timely diagnosis of pneumoperitoneum by point-of-care ultrasound in the emergency department: A case series. *Clin Pract Cases Emerg Med*. 2021;5(4):377-80.
  114. Jiang L, Wu J, Feng X. The value of ultrasound in diagnosis of pneumoperitoneum in emergent or critical conditions: A meta-analysis. *Hong Kong J Emerg Med*. 2019;26(2):111-7.
  115. Robinson A, Light D, Nice C. Meta-analysis of sonography in the diagnosis of inguinal hernias. *J Ultrasound Med*. 2013;32(2):339-46.
  116. Siadecki SD, Frasure SE, Saul T, Lewiss RE. Diagnosis and reduction of a hernia by bedside ultrasound: a case report. *J Emerg Med*. 2014;47(2):169-71.
  117. Bergmann KR, Arroyo AC, Tessaro MO, et al. Diagnostic accuracy of point-of-care ultrasound for intussusception: A multicenter, noninferiority study of paired diagnostic tests. *Ann Emerg Med*. 2021;78(5):606-15.
  118. Lin-Martore M, Kornblith AE, Kohn MA, Gottlieb M. Diagnostic accuracy of point-of-care ultrasound for intussusception in children presenting to the emergency department: A systematic review and meta-analysis. *West J Emerg Med*. 2020;21(4):1008-16.
  119. Kim JH, Lee JY, Kwon JH, Cho HR, Lee JS, Ryu JM. Point-of-care ultrasound could streamline the emergency department workflow of clinically nonspecific intussusception. *Pediatr Emerg Care*. 2020;36(2):e90-e95.
  120. Sivitz AB, Tejani C, Cohen SG. Evaluation of hypertrophic pyloric stenosis by pediatric emergency physician sonography. *Acad Emerg Med*. 2013;20(7):646-51.
  121. Park JS, Byun YH, Choi SJ, Lee JS, Ryu JM, Lee JY. Feasibility of point-of-care ultrasound for diagnosing hypertrophic pyloric stenosis in the emergency department. *Pediatr Emerg Care*. 2021;37(11):550-4.
  122. Gottlieb M, Alerhand S. Managing cardiac arrest using ultrasound [published online ahead of print, 2022 Nov 2]. *Ann Emerg Med*. 2022;S0196-0644(22)01120-9.
  123. Mandavia D, Hoffner R, Mahaney K, et al. Bedside echocardiography by emergency physicians. *Ann Emerg Med*. 2001;38:377-82.
  124. Plummer D, Brunnette D, Asinger R, et al. Emergency department echocardiography improves outcome in penetrating cardiac injury. *Ann Emerg Med*. 1992;21:709-12.

125. Inaba K, Chouliaras K, Zakaluzny, S, et al. FAST Ultrasound Examination as a Predictor of Outcomes After Resuscitative Thoracotomy. *Ann Surg.* 2015;262(3):512-8.
126. Blaiwas M, Fox J. Outcome in cardiac arrest patients found to have cardiac standstill on the bedside emergency department echocardiogram. *Acad Emerg Med.* 2001;8:616-21.
127. Gaspari R, Weekes A, Adhikari S, et al. Emergency department point-of-care ultrasound in out-of-hospital and in-ED cardiac arrest. *Resuscitation.* 2016;109:33-39.
128. Moore CL, Rose GA, Tayal VS, et al. Determination of left ventricular function by emergency physician echocardiography of hypotensive patients. *Acad Emerg Med.* 2002;9(3):186-93.
129. Jones AE, Tayal VS, Sullivan DM, et al. Randomized, controlled trial of immediate versus delayed goal-directed ultrasound to identify the cause of nontraumatic hypotension in emergency department patients. *Crit Care Med.* 2004;32:1703-8.
130. Kanji HD, McCallum J, Sirounis D, et al. Limited echocardiography-guided therapy in subacute shock is associated with change in management and improved outcomes. *J Crit Care.* 2014;29:700-5.
131. Nagdev AD, Merchant RC, Tirado-Gonzalez A, et al. Emergency department bedside ultrasonographic measurement of the caval index for noninvasive determination of low central venous pressure. *Ann Emerg Med.* 2010;55:290-5.
132. Perera P, Mailhot T, Riley D, et al. The RUSH exam: Rapid Ultrasound in SHock in the evaluation of the critically ill. *Emerg Med Clin North Am.* 2010;28(1):29-56.
133. Russell FM, Ehrman RR, Cosby K, et al. Diagnosing acute heart failure in patients with undifferentiated dyspnea: a lung and cardiac ultrasound (LuCUS) protocol. *Acad Emerg Med.* 2015;22:182-91.
134. Martindale JL, Wakai A, Collins SP, et al. Diagnosing acute heart failure in the emergency department: A systematic review and meta-analysis. *Acad Emerg Med.* 2016;23(3):223-42.
135. Rutz MA, Clary JM, Kline JA, et al. Emergency physicians are able to detect right ventricular dilation with good agreement compared to cardiology. *Acad Emerg Med.* 2017;24(7):867-74.
136. Fields JM, Davis J, Girson L, et al. Transthoracic echocardiography for diagnosing pulmonary embolism: A systematic review and meta-analysis. *JASE.* 2017; 30(7):714-723.e4, 2017 Jul.
137. Weekes AJ, Thacker G, Troha D, et al. Diagnostic accuracy of right ventricular dysfunction markers in normotensive emergency department patients with acute pulmonary embolism. *Ann Emerg Med.* 2016;68(3):277-91.
138. Weekes AJ, Raper JD, Lupez K, et al. Development and validation of a prognostic tool: Pulmonary embolism short-term clinical outcomes risk estimation (PE-SCORE). *PLoS One.* 2021;16(11):e0260036.
139. Pomero F, Dentali F, Borretta V, Bonzini M, Melchio R, Douketis JD, Fenoglio LM. Accuracy of emergency physician-performed ultrasonography in the diagnosis of deep-vein thrombosis: A systematic review and meta-analysis. *Thromb Haemost.* 2013;109:137-45.
140. Burnside PR, Brown MD, Kline JA. Systematic review of emergency physician-performed ultrasonography for lower-extremity deep vein thrombosis. *Acad Emerg Med.* 2008;15:493-8.
141. Lee JH, Lee SH, Yun SJ. Comparison of 2-point and 3-point point-of-care ultrasound techniques for deep vein thrombosis at the emergency department: A meta-analysis. *Medicine (Baltimore).* 2019;98(22):e15791.
142. Needleman L, Cronan JJ, Lilly MP, Merli GJ, Adhikari S, Hertzberg BS, DeJong MR, Streiff MB, Meissner MH. Ultrasound for lower extremity deep venous thrombosis: multidisciplinary recommendations from the Society of Radiologists in Ultrasound Consensus Conference. *Circulation.* 2018;137(14):1505-15.
143. Varrias D, Palaiodimos L, Balasubramanian P, et al. The use of point-of-care ultrasound (POCUS) in the diagnosis of deep vein thrombosis. *J Clin Med.* 2021;10(17):3903.
144. Adhikari S, Zeger W, Thom C, Fields JM. Isolated deep venous thrombosis: implications for 2-point compression ultrasonography of the lower extremity. *Ann Emerg Med.* 2015;66:262-6.
145. Frederick MG, Hertzberg BS, Kliewer MA, Paulson EK, Bowie JD, Lalouche KJ, DeLong DM,

- Carroll BA. Can the US examination for lower extremity deep venous thrombosis be abbreviated? A prospective study of 755 examinations. *Radiology*. 1996;199:45-7.
146. Caronia J, Sarzynski A, Tofighi B, Mahdavi R-3. Resident performed two-point compression ultrasound is inadequate for diagnosis of deep vein thrombosis in the critically ill. *J Thromb Thrombolysis*. 2014;37:298-302.
  147. Theodoro D, Blaivas M, Duggal S, et al. Real-time B-mode ultrasound in the ED saves time in the diagnosis of deep vein thrombosis (DVT). *Am J Emerg Med*. 2004;22:197-200.
  148. Oppenheimer DC, Rubens DJ. Sonography of acute cholecystitis and its mimics. *Radiol Clin North Am*. 2019;57(3):535-48.
  149. Blaivas M, Harwood RA, Lambert MJ. Decreasing length of stay with emergency department gallbladder ultrasonography. *Acad Emerg Med*. 1999;6:541.
  150. Villar J, Summers SM, Menchine MD, et al. The absence of gallstones on point-of-care ultrasound rules out acute cholecystitis. *J Emerg Med*. 2015;49:475-80.
  151. Kendall JL, Shimp RJ. Performance and interpretation of limited right upper quadrant ultrasound by emergency physicians. *J Emerg Med*. 2001;21(1):7-13.
  152. Miller AH, Pepe PE, Brockman CR, et al. ED ultrasound in hepatobiliary disease. *J Emerg Med*. 2006;30:69-74.
  153. Ross M, Brown M, McLaughlin K, et al. Emergency physician-performed ultrasound to diagnose cholelithiasis: a systematic review. *Acad Emerg Med*. 2011;18:227-35.
  154. Summers SM, Scruggs W, Menchine MD, et al. A prospective evaluation of emergency department bedside ultrasonography for the detection of acute cholecystitis. *Ann Emerg Med*. 2010;56:114-22.
  155. Graglia S, Shokoohi H, Loesche MA, Yeh DD, Haney RM, Huang CK, Morone CC, Springer C, Kimberly HH, Liteplo AS. Prospective validation of the bedside sonographic acute cholecystitis score in emergency department patients. *Am J Emerg Med*. 2021;42:15-9.
  156. Seyedhosseini J, Nasrelari A, Mohammadrezaei N, Karimialavijeh E. Inter-rater agreement between trained emergency medicine residents and radiologists in the examination of gallbladder and common bile duct by ultrasonography. *Emerg Radiol*. 2017;24(2):171-6.
  157. Lahham S, Becker BA, Gari A, Bunch S, Alvarado M, Anderson CL, Viquez E, Spann SC, Fox JC. Utility of common bile duct measurement in ED point of care ultrasound: A prospective study. *Am J Emerg Med*. 2018;36(6):962-6.
  158. Ripollés T, Martínez-Pérez MJ, Martín G, Vizuete J, Martínez-García R, Diez J, Martí E. Usefulness of contrast-enhanced US in the diagnosis of acute gangrenous cholecystitis: A comparative study with surgical and pathological findings. *Eur J Radiol*. 2016;85(1):31-8.
  159. Secko MA, Reardon L, Gottlieb M, et al. Musculoskeletal ultrasonography to diagnose dislocated shoulders: A prospective cohort. *Ann Emerg Med*. 2020;76(2):119-28.
  160. Gottlieb M, Alerhand S. Ultrasound should be considered for all arthrocentesis. *Ann Emerg Med*. 2020;75(2):261-2.
  161. Wu T, Dong Y, Song H, Fu Y, Li JH. Ultrasound-guided versus landmark in knee arthrocentesis: A systematic review. *Semin Arthritis Rheum*. 2016;45(5):627-32.
  162. Berona K, Abdi A, Menchine M, et al. Success of ultrasound-guided versus landmark-guided arthrocentesis of hip, ankle, and wrist in a cadaver model. *Am J Emerg Med*. 2017;35(2):240-4.
  163. Chartier LB, Bosco L, Lapointe-Shaw L, Chenkin J. Use of point-of-care ultrasound in long bone fractures: a systematic review and meta-analysis. *CJEM*. 2017;19(2):131-42.
  164. Gottlieb M, Cosby K. Ultrasound-guided hematoma block for distal radial and ulnar fractures. *J Emerg Med*. 2015;48(3):310-2.
  165. Bright JM, Fields KB, Draper R. Ultrasound diagnosis of calf injuries. *Sports Health*. 2017;9(4):352-5.
  166. Franks N, Gress J, Joseph R. Point-of-care ultrasound for suspected pectoralis major rupture: A case report. *Clin Pract Cases Emerg Med*. 2021;5(1):93-6.
  167. Schönberger TJ, Ernst MF. A brachialis muscle rupture diagnosed by ultrasound; case report. *Int J*

- Emerg Med.* 2011;4(1):46.
168. Situ-LaCasse E, Grieger RW, Crabbe S, Waterbrook AL, Friedman L, Adhikari S. Utility of point-of-care musculoskeletal ultrasound in the evaluation of emergency department musculoskeletal pathology. *World J Emerg Med.* 2018;9(4):262-6.
  169. Connell DA, Schneider-Kolsky ME, Hoving JL, et al. Longitudinal study comparing sonographic and MRI assessments of acute and healing hamstring injuries. *AJR Am J Roentgenol.* 2004;183:975-84.
  170. Albayda J, van Alfen N. Diagnostic value of muscle ultrasound for myopathies and myositis. *Curr Rheumatol Rep.* 2020;22(11):82.
  171. Kumar MP, Seif D, Perera P, Mailhot T. Point-of-care ultrasound in diagnosing pyomyositis: a report of three cases. *J Emerg Med.* 2014;47(4):420-6.
  172. Bionat ED, Ongchuan MA. The utility of musculoskeletal ultrasonography in diagnosing pyomyositis: a comparison with surgically and conservatively treated cases. *J Diagn Med Sonogr.* 2021;37(3):248-58.
  173. Wu TS, Roque PJ, Green J, Drachman D, Khor KN, Rosenberg M, et al. Bedside ultrasound evaluation of tendon injuries. *Am J Emerg Med.* 2012;30(8):1617-21.
  174. Hubbard D, Joing S, Smith SW. Pyogenic flexor tenosynovitis by point-of-care ultrasound in the emergency department. *Clin Pract Cases Emerg Med.* 2018;2(3):235-40.
  175. Jardin E, Delord M, Aubry S, Loisel F, Obert L. Usefulness of ultrasound for the diagnosis of pyogenic flexor tenosynovitis: A prospective single-center study of 57 cases. *Hand Surg Rehabil.* 2018;37(2):95-8.
  176. Gottlieb M, Holladay D, Peksa GD. Point-of-care ocular ultrasound for the diagnosis of retinal detachment: A systematic review and meta-analysis. *Acad Emerg Med.* 2019;26(8):931-9.
  177. Lahham S, Shniter I, Thompson M, et al. Point-of-care ultrasonography in the diagnosis of retinal detachment, vitreous hemorrhage, and vitreous detachment in the emergency department. *JAMA Netw Open.* 2019;2(4):e192162.
  178. Propst SL, Kirschner JM, Strachan CC, et al. Ocular point-of-care ultrasonography to diagnose posterior chamber abnormalities: A systematic review and meta-analysis. *JAMA Netw Open.* 2020;3(2):e1921460.
  179. Harries A, Shah S, Teismann N, Price D, Nagdev A. Ultrasound assessment of extraocular movements and pupillary light reflex in ocular trauma. *Am J Emerg Med.* 2010 Oct;28(8):956-9.
  180. Aletreby W, Alharthy A, Brindley PG, Kutsogiannis DJ, Faqihi F, Alzayer W, et al. Optic nerve sheath diameter ultrasound for raised intracranial pressure: A literature review and meta-analysis of its diagnostic accuracy. *J Ultrasound Med.* 2022;41(3):585-95.
  181. Teismann N, Lenaghan P, Nolan R, Stein J, Green A. Point-of-care ocular ultrasound to detect optic disc swelling. *Acad Emerg Med.* 2013;20(9):920-5.
  182. Tayal VS, Cohen H, Norton HJ. Outcome of patients with an indeterminate emergency department first-trimester pelvic ultrasound to rule out ectopic pregnancy. *Acad Emerg Med.* 2004;11(9):912-7.
  183. Lewiss RE, Shaikat NM, Saul T. The endomyometrial thickness measurement for abnormal implantation evaluation by pelvic sonography. *J Ultrasound Med.* 2014 Jul;33(7):1143-6.
  184. Wang R, Reynolds TA, West HH, Ravikumar D, Martinez C, McAlpine I, Jacoby VL, Stein JC. Use of a  $\beta$ -hCG discriminatory zone with bedside pelvic ultrasonography. *Ann Emerg Med.* 2011;58(1):12-20.
  185. Stone BS, Muruganandan KM, Tonelli MM, Dugas JN, Verriet IE, Pare JR. Impact of point-of-care ultrasound on treatment time for ectopic pregnancy. *Am J Emerg Med.* 2021 Nov;49:226-32.
  186. Moore C, Todd WM, O'Brien E, Lin H. Free fluid in Morison's pouch on bedside ultrasound predicts need for operative intervention in suspected ectopic pregnancy. *Acad Emerg Med.* 2007 Aug;14(8):755-8.
  187. Stein JC, Wang R, Adler N, Boscardin J, Jacoby VL, Won G, Goldstein R, Kohn MA. Emergency physician ultrasonography for evaluating patients at risk for ectopic pregnancy: a meta-analysis. *Ann Emerg Med.* 2010;56(6):674-83.

188. Saul T, Lewiss RE, Rivera Mdel R. Accuracy of emergency physician performed bedside ultrasound in determining gestational age in first trimester pregnancy. *Crit Ultrasound J*. 2012;4(1):22.
189. Beals T, Naraghi L, Grossestreuer A, Schafer J, Balk D, Hoffmann B. Point of care ultrasound is associated with decreased ED length of stay for symptomatic early pregnancy. *Am J Emerg Med*. 2019;37(6):1165-8.
190. Berzon B, Gleenberg M, Offenbacher J, West D. Atypical presentation of hemorrhagic shock in pregnancy: a case highlighting the developing field of emergency medicine in Israel. *BMC Emerg Med*. 2019;19(1):70. Erratum in: *BMC Emerg Med*. 2020;20(1):4.
191. Derr C, Henry M. Bedside ultrasound in the diagnosis of uterine rupture following surgical abortion. *Emerg Radiol*. 2013;20(2):165-7.
192. Wiese KS, Ernest S, Dukes WS. Case report of traumatic uterine rupture in a multigravida woman with emergency department cesarean section. *Clin Pract Cases Emerg Med*. 2020;4(4):623-5.
193. Adkins K, Minardi J, Setzer E, Williams D. Retained products of conception: An atypical presentation diagnosed immediately with bedside emergency ultrasound. *Case Rep Emerg Med*. 2016;2016:9124967.
194. Brass P, Hellmich M, Kolodziej L, Schick G, Smith AF. Ultrasound guidance versus anatomical landmarks for internal jugular vein catheterization. *Cochrane Database Syst Rev*. 2015;1(1):CD006962.
195. Brass P, Hellmich M, Kolodziej L, Schick G, Smith AF. Ultrasound guidance versus anatomical landmarks for subclavian or femoral vein catheterization. *Cochrane Database Syst Rev*. 2015;1(1):CD011447.
196. Agency for Healthcare Research and Quality. Evidence Report/Technology Assessment: Number 43. Making Health Care Safer. A Critical Analysis of Patient Safety Practices: Summary. Accessed January 2, 2023. Available at: <http://archive.ahrq.gov/clinic/ptsafety/pdf/ptsafety.pdf>.
197. Cattau EL Jr, Benjamin SB, Knuff TE, Castell DO. The accuracy of the physical examination in the diagnosis of suspected ascites. *JAMA*. 1982;247(8):1164-6.
198. Nazeer SR, Dewbre H, Miller AH. Ultrasound-assisted paracentesis performed by emergency physicians vs the traditional technique: a prospective, randomized study. *Am J Emerg Med*. 2005;23(3):363-7.
199. Mercaldi CJ, Lanes SF. Ultrasound guidance decreases complications and improves the cost of care among patients undergoing thoracentesis and paracentesis. *Chest*. 2013;143(2):532-8.
200. Patel PA, Ernst FR, Gunnarsson CL. Ultrasonography guidance reduces complications and costs associated with thoracentesis procedures. *J Clin Ultrasound*. 2012;40(3):135-41.
201. Gordon CE, Feller-Kopman D, Balk EM, Smetana GW. Pneumothorax following thoracentesis: a systematic review and meta-analysis. *Arch Intern Med*. 2010;170(4):332-9.
202. Costantino TG, Satz WA, Dehnkamp W, Goett H. Randomized trial comparing intraoral ultrasound to landmark-based needle aspiration in patients with suspected peritonsillar abscess. *Acad Emerg Med*. 2012;19(6):626-31.
203. Tsang TS, Enriquez-Sarano M, Freeman WK, Barnes ME, Sinak LJ, Gersh BJ, Bailey KR, Seward JB. Consecutive 1127 therapeutic echocardiographically guided pericardiocenteses: clinical profile, practice patterns, and outcomes spanning 21 years. *Mayo Clin Proc*. 2002;77(5):429-36.
204. Lindenberger M, Kjellberg M, Karlsson E, Wranne B. Pericardiocentesis guided by 2-D echocardiography: the method of choice for treatment of pericardial effusion. *J Intern Med*. 2003;253(4):411-7.
205. Gottlieb M, Avila J, Chottiner M, Peksa GD. Point-of-care ultrasonography for the diagnosis of skin and soft tissue abscesses: A systematic review and meta-analysis. *Ann Emerg Med*. 2020;76(1):67-77.
206. Marin JR, Dean AJ, Bilker WB, Panebianco NL, Brown NJ, Alpern ER. Emergency ultrasound-assisted examination of skin and soft tissue infections in the pediatric emergency department. *Acad Emerg Med*. 2013;20(6):545-53.
207. Schmitz GR, Gottlieb M. Managing a cutaneous abscess in the emergency department. *Ann Emerg*



- Med.* 2021;78(1):44-8.
208. Davis J, Czerniski B, Au A, Adhikari S, Farrell I, Fields JM. Diagnostic Accuracy of Ultrasonography in Retained Soft Tissue Foreign Bodies: A Systematic Review and Meta-analysis. *Acad Emerg Med.* 2015;22(7):777-87.
  209. Lahham S, Shniter I, Desai M, Andary R, Saadat S, Fox JC, Pierce S. Point of care ultrasound in the diagnosis of necrotizing fasciitis. *Am J Emerg Med.* 2022;51:397-400.
  210. Yen Z, Wang H, Ma H, Chen S, Chen W. Ultrasonographic screening of clinically-suspected necrotizing fasciitis. *Acad Emerg Med.* 2002;9(12):1448-51.
  211. Wright S, Hoffmann B. Emergency ultrasound of acute scrotal pain. *Eur J Emerg Med.* 2015;22(1):2-9.
  212. Ramanathan S, Bertolotto M, Freeman S, et al. Imaging in scrotal trauma: a European Society of Urogenital Radiology Scrotal and Penile Imaging Working Group (ESUR-SPIWG) position statement. *Eur Radiol.* 2021;31:4918-28.
  213. Ota K, Fukui K, Oba K, et al. The role of ultrasound imaging in adult patients with testicular torsion: a systematic review and meta-analysis. *J Med Ultrasonics.* 2019;46:325-34.
  214. Liang T, Metcalfe P, Sevcik W, Noga M. Retrospective review of diagnosis and treatment in children presenting to the pediatric department with acute scrotum. *AJR Am J Roentgenol.* 2013;200:5.
  215. Blaivas M, Sierzenski P. Emergency ultrasonography in the evaluation of the acute scrotum. *Acad Emerg Med.* 2001;8(1):85-9.
  216. Blaivas M, Sierzenski P, Lambert M. Emergency evaluation of patients presenting with acute scrotum using bedside ultrasonography. *Acad Emerg Med.* 2001;8(1):90-3.
  217. Friedman N, Pancer Z, Savic R, Tseng F, Lee MS, Mclean L, Bagli DJ, Tessaro MO. Accuracy of point-of-care ultrasound by pediatric emergency physicians for testicular torsion. *J Pediatr Urol.* 2019;15(6):608.e1-608.e6.
  218. McDowall J, Adam A, Gerber L, et al. The ultrasonographic “whirlpool sign” in testicular torsion: valuable tool or waste of valuable time? A systematic review and meta-analysis. *Emerg Radiol.* 2018;25:281-92.
  219. Morrison D, Blaivas M, Lyon M. Emergency diagnosis of Fournier's gangrene with bedside ultrasound. *Am J Emerg Med.* 2005;23(4):544-7.
  220. Sadjó SA, Destinval C, Lemelle JL, Berte N. Testicular rupture after blunt scrotal trauma in children: A case report and literature review. *Trauma Case Rep.* 2021;33:100482.
  221. McGiverty K, Atkinson P, Lewis D, et al. Emergency department ultrasound for the detection of B-lines in the early diagnosis of acute decompensated heart failure: a systematic review and meta-analysis. *CJEM.* 2018;20(3):343-52.
  222. Orso D, Guglielmo N, Copetti R. Lung ultrasound in diagnosing pneumonia in the emergency department: a systematic review and meta-analysis. *Eur J Emerg Med.* 2018;25(5):312-21.
  223. Alzahrani SA, Al-Salamah MA, Al-Madani WH, et al. Systematic review and meta-analysis for the use of ultrasound versus radiology in diagnosing of pneumonia. *Crit Ultrasound J.* 2017;9(1):6.
  224. Lu X, Jin Y, Li Y, et al. Diagnostic accuracy of lung ultrasonography in childhood pneumonia: a meta-analysis. *Eur J Emerg Med.* 2022;29(2):105-17.
  225. Pereda MA, Chavez MA, Hooper-Miele CC, et al. Lung ultrasound for the diagnosis of pneumonia in children: a meta-analysis. *Pediatrics.* 2015;135(4):714-22.
  226. Gil-Rodriguez J, de Rojas JP, Aranda-Laserna P, et al. Ultrasound findings of lung ultrasonography in COVID-19: A systematic review. *Eur J Radiol.* 2022;148:110156.
  227. Hosseini M, Ghelichkhani P, Baikpour M, et al. Diagnostic accuracy of ultrasonography and radiography in detection of pulmonary contusion; a systematic review and meta-Analysis. *Emerg (Tehran).* 2015;3(4):127-36.
  228. Hansell L, Milross M, Delaney A, et al. Lung ultrasound has greater accuracy than conventional respiratory assessment tools for the diagnosis of pleural effusion, lung consolidation and collapse: a systematic review. *J Physiother.* 2021;67(1):41-8.

229. Zare MA, Bahmani A, Fathi M, et al. Role of point-of-care ultrasound study in early disposition of patients with undifferentiated acute dyspnea in emergency department: a multi-center prospective study. *J Ultrasound*. 2022;25(3):443-9.
230. Gottlieb M, Holladay D, Burns KM, Nakitende D, Bailitz J. Ultrasound for airway management: An evidence-based review for the emergency clinician. *Am J Emerg Med*. 2020;38(5):1007-13.
231. Adhikari S, Zeger W, Schmier C, et al. Pilot study to determine the utility of point-of-care ultrasound in the assessment of difficult laryngoscopy. *Acad Emerg Med*. 2011;18(7):754-8.
232. Gottlieb M, Holladay D, Peksa GD. Ultrasonography for the Confirmation of Endotracheal Tube Intubation: A Systematic Review and Meta-Analysis. *Ann Emerg Med*. 2018;72(6):627-36.
233. Gottlieb M, Holladay D, Serici A, Shah S, Nakitende D. Comparison of color flow with standard ultrasound for the detection of endotracheal intubation. *Am J Emerg Med*. 2018;36(7):1166-9.
234. Gottlieb M, Nakitende D, Sundaram T, Serici A, Shah S, Bailitz J. Comparison of Static versus Dynamic Ultrasound for the Detection of Endotracheal Intubation. *West J Emerg Med*. 2018;19(2):412-6.
235. Gottlieb M, Holladay D, Burns K, et al. Accuracy of ultrasound for endotracheal intubation between different transducer types. *Am J Emerg Med*. 2019;37(12):2182-5.
236. Gottlieb M, Holladay D, Nakitende D, et al. Variation in the accuracy of ultrasound for the detection of intubation by endotracheal tube size. *Am J Emerg Med*. 2019;37(4):706-9.
237. Gottlieb M, Burns K, Holladay D, Chottiner M, Shah S, Gore SR. Impact of endotracheal tube twisting on the diagnostic accuracy of ultrasound for intubation confirmation. *Am J Emerg Med*. 2020;38(7):1332-4.
238. Gottlieb M, Alerhand S, Long B. Point-of-Care Ultrasound for Intubation Confirmation of COVID-19 Patients. *West J Emerg Med*. 2020;21(5):1042-5.
239. Gottlieb M, Patel D, Sundaram T. Comparison of endotracheal tube location on ultrasound accuracy, time, and confidence. *Am J Emerg Med*. 2022 Dec;62:127-128.
240. Link MS, Berkow LC, Kudenchuk PJ, et al. Part 7: Adult Advanced Cardiovascular Life Support: 2015 American Heart Association Guidelines Update for Cardiopulmonary Resuscitation and Emergency Cardiovascular Care. *Circulation*. 2015;132(18 Suppl 2):S444-S464.
241. Mallin M, Curtis K, Dawson M, Ockerse P, Ahern M. Accuracy of ultrasound-guided marking of the cricothyroid membrane before simulated failed intubation. *Am J Emerg Med*. 2014;32(1):61-3.
242. Siddiqui N, Yu E, Boulis S, You-Ten KE. Ultrasound Is Superior to Palpation in Identifying the Cricothyroid Membrane in Subjects with Poorly Defined Neck Landmarks: A Randomized Clinical Trial. *Anesthesiology*. 2018;129(6):1132-9.
243. Curtis K, Ahern M, Dawson M, Mallin M. Ultrasound-guided, Bougie-assisted cricothyroidotomy: a description of a novel technique in cadaveric models. *Acad Emerg Med*. 2012;19(7):876-9.
244. ATLS Subcommittee; American College of Surgeons' Committee on Trauma; International ATLS working group. Advanced trauma life support (ATLS®): the ninth edition. *J Trauma Acute Care Surg*. 2013;74(5):1363-6.
245. Pearl WS, Todd KH. Ultrasonography for the initial evaluation of blunt abdominal trauma: A review of prospective trials. *Ann Emerg Med*. 1996;27(3):353-61.
246. American Institute of Ultrasound in Medicine; American College of Emergency Physicians. AIUM practice guideline for the performance of the focused assessment with sonography for trauma (FAST) examination. *J Ultrasound Med*. 2014;33(11):2047-56. Accessed December 2022 at: <https://www.aium.org/resources/guidelines/fast.pdf>
247. Jahanshir A, Moghari SM, Ahmadi A, Moghadam PZ, Bahreini M. Value of point-of-care ultrasonography compared with computed tomography scan in detecting potential life-threatening conditions in blunt chest trauma patients. *Ultrasound J*. 2020;12(1):36.
248. Volpicelli G, Elbarbary M, Blaivas M, et al. International evidence-based recommendations for point-of-care lung ultrasound. *Intensive Care Med*. 2012;38:577-91.
249. Governatori NJ, Saul T, Siadecki SD, Lewiss RE. Ultrasound in the evaluation of penetrating

- thoraco-abdominal trauma: a review of the literature. *Med Ultrason*. 2015;17(4):528-34.
250. Melniker LA, Leibner E, McKenney MG, Lopez P, Briggs WM, Mancuso CA. Randomized controlled clinical trial of point-of-care, limited ultrasonography for trauma in the emergency department: the first sonography outcomes assessment program trial. *Ann Emerg Med*. 2006;48(3):227-35.
  251. Sheng AY, Dalziel P, Liteplo AS, et al. Focused assessment with sonography in trauma and abdominal computed tomography utilization in adult trauma patients: Trends over the last decade. *Emerg Med Int*. 2013;2013:678380.
  252. American College of Emergency Physicians. Ultrasound Guided Nerve Blocks [policy statement]. Approved April 2021. Accessed November 18, 2022. Available from: <https://www.acep.org/globalassets/new-pdfs/policy-statements/ultrasound-guided-nerve-blocks.pdf>
  253. Welch MB, Brummett CM, Welch TD, Tremper KK, Shanks AM, Guglani P, Mashour GA. Perioperative peripheral nerve injuries: a retrospective study of 380,680 cases during a 10-year period at a single institution. *Anesthesiology*. 2009;111(3):490-7.
  254. Sites BD, Barrington MJ, Davis M. Using an international clinical registry of regional anesthesia to identify targets for quality improvement. *Reg Anesth Pain Med*. 2014;39(6):487-95.
  255. Raeyat Doost E, Heiran MM, Movahedi M, Mirafzal A. Ultrasound-guided interscalene nerve block vs procedural sedation by propofol and fentanyl for anterior shoulder dislocations. *Am J Emerg Med*. 2017;35(10):1435-9.
  256. Abdelhamid K, ElHawary H, Turner JP. The use of the erector spinae plane block to decrease pain and opioid consumption in the emergency department: A literature review. *J Emerg Med*. 2020;58(4):603-9.
  257. Tekşen Ş, Öksüz G, Öksüz H, Sayan M, Arslan M, Urfaloğlu A, Gişi G, Bilal B. Analgesic efficacy of the serratus anterior plane block in rib fractures pain: A randomized controlled trial. *Am J Emerg Med*. 2021;41:16-20.
  258. Surdhar I, Jelic T. The erector spinae plane block for acute pain management in emergency department patients with rib fractures. *CJEM*. 2022;24(1):50-4.
  259. Aydin ME, Tekin E, Ahiskalioglu EO, Ates I, Karagoz S, Aydin OF, Ozkaya F, Ahiskalioglu A. Erector spinae plane block vs non-steroidal anti-inflammatory drugs for severe renal colic pain: A pilot clinical feasibility study. *Int J Clin Pract*. 2021;75(3):e13789.
  260. Herring AA, Stone MB, Nagdev AD. Ultrasound-guided abdominal wall nerve blocks in the ED. *Am J Emerg Med*. 2012;30(5):759-64.
  261. Mahmoud S, Miraflor E, Martin D, Mantuani D, Luftig J, Nagdev AD. Ultrasound-guided transverse abdominis plane block for ED appendicitis pain control. *Am J Emerg Med*. 2019;37(4):740-3.
  262. Brox WT, Roberts KC, Taksali S, Wright DG, Wixted JJ, Tubb CC, et al. The American Academy of Orthopaedic Surgeons Evidence-Based Guideline on Management of Hip Fractures in the Elderly. *J Bone Joint Surg Am*. 2015;97(14):1196-9.
  263. American College of Surgeons. Best practices guidelines for acute pain management in trauma patients. November 2020. Available at: [https://www.facs.org/-/media/files/quality-programs/trauma/tqip/acute\\_pain\\_guidelines.ashx](https://www.facs.org/-/media/files/quality-programs/trauma/tqip/acute_pain_guidelines.ashx)
  264. Guay J, Kopp S. Peripheral nerve blocks for hip fractures in adults. *Cochrane Database Syst Rev*. 2020 Nov 25;11(11):CD001159.
  265. Kolodychuk N, Krebs JC, Stenberg R, Talmage L, Meehan A, DiNicola N. Fascia iliaca blocks performed in the emergency department decrease opioid consumption and length of stay in patients with hip fracture. *J Orthop Trauma*. 2022;36(3):142-6.
  266. Makkar JK, Singh NP, Bhatia N, Samra T, Singh PM. Fascia iliaca block for hip fractures in the emergency department: meta-analysis with trial sequential analysis. *Am J Emerg Med*. 2021;50:654-60.
  267. Luftig J, Dreyfuss A, Mantuani D, Howell K, White A, Nagdev A. A new frontier in pelvic fracture pain control in the ED: Successful use of the pericapsular nerve group (PENG) block. *Am J Emerg*

- Med.* 2020;38(12):2761.e5-2761.e9.
268. Goldsmith AJ, Liteplo A, Hayes BD, Duggan N, Huang C, Shokoohi H. Ultrasound-guided transgluteal sciatic nerve analgesia for refractory back pain in the ED. *Am J Emerg Med.* 2020;38(9):1792-5.
  269. Cisewski DH, Alerhand S. 'SCALD-ED' Block: Superficial Cutaneous Anesthesia in a Lateral Leg Distribution within the Emergency Department - A Case Series. *J Emerg Med.* 2019;56(3):282-7.
  270. Vrablik M, Akhavan A, Murphy D, Schrepel C, Hall MK. Ultrasound-guided nerve blocks for painful hand injuries: A randomized control trial. *Cureus.* 2021;13(10):e18978.
  271. Moore CL, Carpenter CR, Heilbrun ME, et al. Imaging in suspected renal colic: systematic review of the literature and multispecialty consensus. *Ann Emerg Med.* 2019;74(3):391-9.
  272. Park YH, Jung RB, Lee YG, et al. Does the use of bedside ultrasonography reduce emergency department length of stay for patients with renal colic?: a pilot study. *Clin Exp Emerg Med.* 2016;3(4):197-203.
  273. Wong C, Teitge B, Ross M, Young P, Robertson HL, Lang E. The accuracy and prognostic value of point-of-care ultrasound for nephrolithiasis in the emergency department: A systematic review and meta-analysis. *Acad Emerg Med.* 2018;25(6):684-98.
  274. Smith-Bindman R, Aubin C, Bailitz J, et al. Ultrasonography versus computed tomography for suspected nephrolithiasis. *N Engl J Med.* 2014;371:1100-10.
  275. Herbst MK, Rosenberg G, Daniels B, et al. Effect of provider experience on clinician-performed ultrasonography for hydronephrosis in patients with suspected renal colic. *Ann Emerg Med.* 2014;64(3):269-76.
  276. Daniels B, Gross CP, Molinaro A, et al. STONE PLUS: Evaluation of emergency department patients with suspected renal colic, using a clinical prediction tool combined with point-of-care limited ultrasonography. *Ann Emerg Med.* 2016;67(4):439-48.
  277. Witt M, Baumann BM, McCans K. Bladder ultrasound increases catheterization success in pediatric patients. *Acad Emerg Med.* 2005;12(4):371-4.
  278. Lambert MJ, Villa M. Gynecologic ultrasound in emergency medicine. *Emerg Med Clin North Am.* 2004;22(3):683-96.
  279. Tayal VS, Crean CA, Norton HJ, Schulz CJ, Bacalis KN, Bliss S. Prospective comparative trial of endovaginal sonographic bimanual examination versus traditional digital bimanual examination in nonpregnant women with lower abdominal pain with regard to body mass index classification. *J Ultrasound Med.* 2008;27(8):1171-7.
  280. Houry D, Abbott JT. Ovarian torsion: a fifteen-year review. *Ann Emerg Med.* 2001;38(2):156-9.
  281. Johnson S, Fox JC, Koenig KL. Diagnosis of ovarian torsion in a hemodynamically unstable pediatric patient by bedside ultrasound in the ED. *Am J Emerg Med.* 2006;24(4):496-7.
  282. Lee DC, Swaminathan AK. Sensitivity of ultrasound for the diagnosis of tubo-ovarian abscess: a case report and literature review. *J Emerg Med.* 2011;40(2):170-5.
  283. Adhikari S, Blaivas M, Lyon M. Role of bedside transvaginal ultrasonography in the diagnosis of tubo-ovarian abscess in the emergency department. *J Emerg Med.* 2008;34(4):429-33.
  284. Bellapu S, Guttman J. Use of point-of-care ultrasound for the diagnosis of ovarian hyperstimulation syndrome. *J Emerg Med.* 2017;52(4):e101-e104.
  285. Hall MK, Coffey EC, Herbst M, Liu R, Pare JR, Taylor RA, Thomas S, Moore CL. The 5Es of emergency physician-performed focused cardiac ultrasound: a protocol for rapid identification of effusion, ejection, equality, exit and entrance. *Acad Emerg Med.* 2015;22(5):583-93.
  286. Alerhand S, Adrian RJ, Long B, Avila J. Pericardial tamponade: A comprehensive emergency medicine and echocardiography review. *Am J Emerg Med.* 2022;58:159-74.
  287. Ehrman RR, Russel FM, Ansari AH, Margeta B, Clary JM, Christian E, Cosby KS, Bailitz J. Can emergency physicians diagnose and correctly classify diastolic dysfunction using bedside echocardiography? *Am J Emerg Med.* 2015;33(9):1178-83.
  288. Del Rios M, Colla J, Kotini-Shah P, Briller J, Gerber B, Prendergast H. Emergency physician use of

- tissue Doppler bedside echocardiography in detecting diastolic dysfunction: an exploratory study. *Crit Ultrasound J*. 2018;10(1):4.
289. Alerhand S, Sundaram T, Gottlieb M. What are the echocardiographic findings of acute right ventricular strain that suggest pulmonary embolism? *Anaesth Crit Care Pain Med*. 2021;40(2):100852.
  290. Daley J, Grotberg J, Pare J, Medoro A, Liu R, Hall MK, Taylor A, Moore CL. Emergency physician performed tricuspid annular plane systolic excursion in the evaluation of suspected pulmonary embolism. *Am J Emerg Med*. 2017;35(1):106-11.
  291. Shah BR, Velamakanni WM, Patel A, Khadkikar G, Patel TM, Shah SC. Analysis of the 60/60 sign and other right ventricular parameters by 2D transthoracic echocardiography as adjuncts to diagnosis of acute pulmonary embolism. *Cureus*. 2021;13(3): e13800.
  292. Croft PE, Strout TD, Kring RM, Director L, Vasaiwala SC, Mackenzie DC. WAMAMI: emergency physicians can accurately identify wall motion abnormalities in acute myocardial infarction. *Am J Emerg Med*. 2019;37(12): 2224-8.
  293. Saglam C, Unluer EE, Yamanoglu NGC, Kara PH, Ediboglu E, Bektasli R, Tandon S, Gonulu H. Accuracy of emergency physicians for detection of regional wall motion abnormalities in patients with chest pain without ST-elevation myocardial infarction. *J Ultrasound Med*. 2021;40(7):1335-42.
  294. Dinh VA, Ko HS, Rao R, Bansal RC, Smith DD, Kin TE, Nguyen HB. Measuring cardiac index with a focused cardiac ultrasound examination in the ED. *Am J Emerg Med*. 2012;30(9):1845-51.
  295. MacKenzie DC, Khan NA, Blehar D, Glazier S, Chang Y, Stowell CP, Noble VE, Liteplo AS. Carotid flow time changes with volume status in acute blood loss. *Ann Emerg Med*. 2015;66(3):277-282.
  296. Hu K, Gupta N, Teran F, Saul T, Nelson BP, Andrus P. Variability in interpretation of cardiac standstill among physician sonographers. *Ann Emerg Med*. 2018;71(2):193-8.
  297. Clattenburg EJ, Wroe PC, Gardner K, Schultz C, Gelber J, Singh A, Nagdev A. Implementation of the cardiac arrest sonographic assessment (CASA) protocol for patients with cardiac arrest is associated with shorter CPR pulse checks. *Resuscitation*. 2018;131:69-73.
  298. Liu RB, Bogucki S, Marcolini EG, Yu CY, Wira CR, Kalam S, Daley J, Moore CL, Cone DC. Guiding cardiopulmonary resuscitation with focused echocardiography: a report of five cases. *Prehosp Emerg Care*. 2020;24(2): 297-302.
  299. Gaspari R, Weekes A, Adhikari S, Noble V, Nomura JT, Theodoro D, et al. A retrospective study of pulseless electrical activity, bedside ultrasound identifies interventions during resuscitation associated with improved survival to hospital admission. A REASON study. *Resuscitation*. 2017;120:103-7.
  300. Kummer T, Oh L, Phelan MB, Huang RD, Nomura JT, Adhikari S. Emergency and critical care applications for contrast-enhanced ultrasound. *Am J Emerg Med*. 2018;36(7):1287-94.
  301. Catalano O, Aiani L, Barozzi L, Bokor D, De Marchi A, Faletti C, et al. CEUS in abdominal trauma: multi-center study. *Abdom Imaging*. 2009;34(2):225-34.
  302. Tang C, Fang K, Guo Y, Li R, Fan X, Chen P, et al. Safety of sulfur hexafluoride microbubbles in sonography of abdominal and superficial organs: retrospective analysis of 30,222 cases. *J Ultrasound Med*. 2017;36(3):531-8.
  303. Catalano O, Lobianco R, Cusati B, Siani A. Contrast-enhanced sonography for diagnosis of ruptured abdominal aortic aneurysm. *AJR Am J Roentgenol*. 2005;184(2):423-7.
  304. El Kadi S, Porter TR, Verouden N, van Rossum A, Kamp O. Contrast ultrasound, sonothrombolysis and sonoperfusion in cardiovascular disease: shifting to therapeutic clinical trials. *JACC Cardiovasc Imaging*. 2021 Oct 7;S1936-878X(21)00689-6.
  305. Emanuel A, Meijer R, Poelgeest E, Spoor P, Serne E, Eringa E. Contrast-enhanced ultrasound for quantification of tissue perfusion in humans. *Microcirculation*. 2020;27(1):e12588.
  306. Hakim SM, Abdellatif AA, Ali MI, Ammar MA. Reliability of transcranial sonography for assessment of brain midline shift in adult neurocritical patients: a systematic review and meta-analysis. *Minerva Anesthesiol*. 2021;87(4):467-75.

307. Kumar G, Shahripour RB, Harrigan MR. Vasospasm on transcranial Doppler is predictive of delayed cerebral ischemia in aneurysmal subarachnoid hemorrhage: a systematic review and meta-analysis. *J Neurosurg*. 2016;124(5):1257-64.
308. Zhang XH, Liang HM. Systematic review with network meta-analysis: Diagnostic values of ultrasonography, computed tomography, and magnetic resonance imaging in patients with ischemic stroke. *Medicine (Baltimore)*. 2019;98(30):e16360.
309. Fernando SM, Tran A, Cheng W, et al. Diagnosis of elevated intracranial pressure in critically ill adults: systematic review and meta-analysis. *BMJ*. 2019;366:l4225.
310. Chang JJ, Tsvigoulis G, Katsanos AH, Malkoff MD, Alexandrov AV. Diagnostic Accuracy of Transcranial Doppler for Brain Death Confirmation: Systematic Review and Meta-Analysis. *AJNR Am J Neuroradiol*. 2016;37(3):408-14.
311. van der Wouw PA, Koster RW, Delemarre BJ, et al. Diagnostic accuracy of transesophageal echocardiography during cardiopulmonary resuscitation. *J Am Coll Cardiol*. 1997;30(3):780-3.
312. Varriale P, Maldonado JM. Echocardiographic observations during in hospital cardiopulmonary resuscitation. *Crit Care Med*. 1997;25(10):1717-20.
313. Miyake M, Izumi C, Takahashi S, et al. Efficacy of transesophageal echocardiography in patients with cardiac arrest or shock. *J Cardiol*. 2004;44(5):189-94.
314. Memtsoudis SG, Rosenberger P, Loffler M, et al. The usefulness of transesophageal echocardiography during intraoperative cardiac arrest in noncardiac surgery. *Anesth Analg*. 2006;102(6):1653-7.
315. Lin T, Chen Y, Lu C, et al. Use of transoesophageal echocardiography during cardiac arrest in patients undergoing elective non-cardiac surgery. *Br J Anaesth*. 2006;96(2):167-70.
316. Shillcutt SK, Markin NW, Montzingo CR, et al. Use of rapid "rescue" perioperative echocardiography to improve outcomes after hemodynamic instability in noncardiac surgical patients. *J Cardiothorac Vasc Anesth*. 2012;26(3):362-70.
317. Hilberath JN, Burrage PS, Shernan SK, et al. Rescue transoesophageal echocardiography for refractory haemodynamic instability during transvenous lead extraction. *Eur Heart J Cardiovasc Imaging*. 2014;15(8):926-32.
318. Arntfield R, Pace J, Hewak M, Thompson D. Focused transesophageal echocardiography by emergency physicians is feasible and clinically influential: observational results from a novel ultrasound program. *J Emerg Med*. 2016;50(2):286-94.
319. Reardon RF, Chinn E, Plummer D, et al. Feasibility, utility, and safety of fully incorporating transesophageal echocardiography into emergency medicine practice. *Acad Emerg Med*. 2022;29(3):334-43.
320. Hwang SO, Zhao PG, Choi HJ, et al. Compression of the left ventricular outflow tract during cardiopulmonary resuscitation. *Acad Emerg Med*. 2009;16(10):928-33.
321. Cha KC, Kim YJ, Shin HJ, et al. Optimal position for external chest compression during cardiopulmonary resuscitation: an analysis based on chest CT in patients resuscitated from cardiac arrest. *Emerg Med J*. 2013;30(8):615-9.
322. Teran F, Dean AJ, Centeno C, et al.; Evaluation of out-of-hospital cardiac arrest using transesophageal echocardiography in the emergency department. *Resuscitation*. 2019;137:140-7.
323. Catena E, Ottolina D, Fossali T, et al. Association between left ventricular outflow tract opening and successful resuscitation after cardiac arrest. *Resuscitation*. 2019;138:8-14.
324. Fair J 3rd, Mallin MP, Adler A, et al. Transesophageal echocardiography during cardiopulmonary resuscitation is associated with shorter compression pauses compared with transthoracic echocardiography. *Ann Emerg Med*. 2019;73(6):610-6.
325. Lerner RP, Haaland A, Lin J. Temporary transvenous pacer placement under transesophageal echocardiogram guidance in the Emergency Department. *Am J Emerg Med*. 2020;38(5):1044.e3-1044.e4.
326. Fair J, Tonna J, Ockerse P. Emergency physician-performed transesophageal echocardiography for

- extracorporeal life support vascular cannula placement. *Am J Emerg Med.* 2016; 34(8):1637-9.
327. Teran F, Abella B. (2021, July - ). Resuscitative TEE collaborative registry (rTEECORE). Identifier NCT04972526. <https://www.clinicaltrials.gov/ct2/show/NCT04972526>